

Diagnostic Performance of Multidetector Computed Tomography for Detecting Aorto-Ostial Lesions Compared With Catheter Coronary Angiography: Multidetector Computed Tomography Coronary Angiography Is Superior to Catheter Angiography in Detection of Aorto-Ostial Lesions

Mecit Kantarci, MD,* Naci Ceviz, MD,† Serdar Sevimli, MD,‡ Ummugulsum Bayraktutan, MD,* Elvan Ceyhan, PhD,§ Cihan Duran, MD,|| Adem Karaman, MD,* Irmak Durur, MD,* and Adnan Okur, MD*

Purpose: In this study, our goal is to determine the use of multidetector computed tomography (MDCT) in detection of aorto-ostial lesions.

Materials and Methods: Thirty-three patients suspected to have aorto-ostial lesion by either catheter angiography (CA) or MDCT coronary angiography comprised our study population. In 19 patients (group 1), aorto-ostial lesion was suspected based on CA, then MDCT coronary angiography was performed. In the remaining 14 patients (group 2), aorto-ostial lesion diagnosis was made by MDCT coronary angiography, and then afterward, CA was performed. A cardiologist and a radiologist reevaluated both the CA and MDCT coronary angiography recordings of all patients and their consensus formed the diagnosis. We accepted this consensus diagnosis as our criterion standard because a universal criterion standard to compare CA and MDCT findings with is not available. Then, the previous diagnoses by CA and MDCT coronary angiography were compared with the consensus diagnoses.

Results: Finally, 26 patients were diagnosed with aorto-ostial lesion, whereas 5 patients were found not to have aorto-ostial lesions. Two patients were diagnosed with abnormal origination of a coronary artery. When the results were evaluated in terms of the presence of aorto-ostial lesion, MDCT coronary angiography correctly diagnosed all 26 patients, and in the 5 patients with normal ostium, MDCT coronary angiography finding was also normal. However, 7 of 26 patients with aorto-ostial lesion were reported to be normal by CA, and also 5 patients with normal ostia were reported to have aorto-ostial lesion by CA. That is, 12 of 33 patients were misdiagnosed by CA. Moreover, CA missed the abnormal origination of the coronary arteries in 2 patients. When the results were evaluated in terms of the degree of stenosis in 26 patients with aorto-ostial lesion; MDCT coronary angiography predicted the final diagnosis in all 26 patients

correctly. However, CA predicted the final degree of stenosis only in 12 patients. Catheter angiography underestimated the degree of the stenosis in 2 patients, overestimated in 5 patients and missed the lesion in 7 patients.

Conclusions: Our findings suggest that MDCT is a reliable tool for diagnosing the presence and severity of aorto-ostial lesions. In addition, MDCT might be useful in preventing the false diagnosis due to the catheter-induced spasms in patients who were diagnosed with aorto-ostial lesion by CA. Moreover, if MDCT coronary angiography detects a lesion in aorto-ostial region, there is no need to perform CA to merely verify this pathology.

Key Words: MDCT angiography, aorto-ostial lesions, catheter angiography

(*J Comput Assist Tomogr* 2007;31:595–599)

Coronary artery diseases represent the major cause of morbidity and mortality in developed countries.¹ Aorto-ostial lesions are among the most important types of coronary artery diseases, and they occur within the first 3 mm of the main coronary vessel as the vessel splits from aorta. Such a lesion constitutes a case of clinical emergency especially for left main coronary artery (LMCA) and requires accurate diagnosis and treatment.²

Catheter angiography (CA) is currently the criterion standard in diagnosing coronary artery stenosis.³ Nevertheless, detection of aorto-ostial lesions may be elusive during invasive CA because of catheter-induced spasms, anomalous origination of the coronary arteries, or positioning of the catheter tip beyond the arterial ostium which can mask the lesion. Recent advances in computed tomography (CT) techniques, such as multidetector computed tomography (MDCT) scanners, made it possible to visualize the coronary arteries in 3-dimensional (3D).^{4–7} Because of its advantages such as multiplicity of detectors, faster speed of gantry rotation and sophisticated algorithms for reconstructing partial scan data, and recombining data from various phases, MDCT is a reliable and noninvasive tool for diagnosing coronary stenosis.^{8,9}

From the *Department of Radiology, †Division of Pediatric Cardiology, and ‡Department of Cardiology, Medical Faculty, Atatürk University, Erzurum; §Department of Mathematics, College of Arts and Sciences, Koç University, Istanbul, Turkey; and ||Department of Radiology, Florence Nightingale Hospital, Istanbul, Turkey.

Received for publication August 9, 2006; accepted October 16, 2006.

Reprints: Mecit Kantarci, MD, 200 Evler Mah. 14. Sok No 5, Dadaskent, Erzurum, Turkey (e-mail: akkanrad@hotmail.com).

Copyright © 2007 by Lippincott Williams & Wilkins

Therefore, it can also be used to discover the aorto-ostial lesions in vivo. In this study, our goal is to determine the use of MDCT in detection of aorto-ostial lesions. We demonstrate that MDCT coronary angiography does not have the above-mentioned problems of CA. In the English literature, to our knowledge, this is the first study in which such a large group of patients was evaluated.

MATERIALS AND METHODS

Patient Population

Thirty-three patients with suspected aorto-ostial lesion by either CA or MDCT coronary angiography from Ataturk University Hospital and Florence Nightingale Hospital comprised our study population. Each of these patients was examined for atypical chest pain and other symptoms suggestive of coronary artery disease.

In 19 patients (group 1), aorto-ostial lesion was suspected based on CA. The cardiologist who performed the CA recorded his diagnoses. Nitroglycerin was given during CA to the patients suspected with catheter-induced spasm, and then, the CA was repeated a few minutes later. Standard left anterior oblique and right anterior oblique views, and steep cranial and caudal angulations were used for imaging main coronary ostia clearly. Patients who were assessed as healthy after these maneuvers were excluded from the study.

Then, a radiologist performed MDCT coronary angiography. The radiologist knew of only the presence of aorto-ostial lesions from the cardiologist, but he was unaware of the localization of the lesion and degree of the stenosis.

In the remaining 14 patients (group 2), aorto-ostial lesion diagnosis was made by MDCT coronary angiography by the radiologist. Then, CA was performed as an alternative by the cardiologist. The cardiologist only had the information of presence of aorto-ostial lesions.

A cardiologist (8 years of experience with CA) and a radiologist (4 years of experience with MDCT coronary angiography) reevaluated both CA and MDCT coronary angiography recordings of all patients, and their consensus formed the final diagnosis. Therefore, we have not a chance like using an independent criterion standard such as intracoronary ultrasound; we accepted this consensus diagnosis as our criterion standard because a universal criterion standard was not present at our disposal. Then, the previous diagnoses by CA and MDCT coronary angiography were compared with the consensus diagnosis (ie, diagnosis in the criterion standard).

Patients did not have contraindications for MDCT coronary angiography such as irregular heart rate and renal failure (serum creatinine, >1.5 mg/dL). The patients were between the ages of 35 and 75 years (mean \pm SD, 58 ± 12.28 years). Eighteen patients (55%) were men and 15 patients (45%) were women. The procedures used were in accordance with the recommendations found in the Helsinki declaration. Informed consent was obtained from each patient.

Premedication

Patients were in sinus rhythm and were always premedicated with nitroglycerin (5 mg sublingual 1 min

before the examination) to dilate the coronary arteries and, if necessary, with metoprolol tartrate (5 mg/mL IV bolus; Beloc ampule; AstraZeneca, Istanbul, Turkey) to decrease the heart rate. The heart rate of all the patients varied between 50 and 70 beats/min with or without premedication.

MDCT Scan Protocol and Image Analysis

The MDCT was performed on 2 different 16-MDCT scanners (Sensation 16, Siemens Medical Solutions, Erlangen, Germany or Aquillon, Toshiba Medical Systems, Tokyo, Japan) during 1 breath hold (16–24 seconds). With the first scanner, the following parameters were applied: 12×0.75 -mm collimation, 1-mm slice thickness, and 0.6-mm reconstruction interval. On the second scanner, images were obtained with 16×0.5 -mm collimation, 1.0-mm slice thickness, and 1.0-mm reconstruction interval. Eighty-five milliliters of iodinated contrast medium (iohexol [Omnipaque; Amersham Health, Cork, Ireland]) was injected intravenously at 4.5 mL/s followed by 40 mL of saline at 2.5 mL/s. The CT scans were obtained from 1 cm below the carina to the diaphragmatic face of the heart during a single breath-holding period with retrospective electrocardiogram gating.

Retrospective electrocardiogram-gated reconstructions were generated at 50%, 60%, 70%, 75%, and 80% of the R-R interval. Among these different data sets, the best ones for evaluation of right coronary artery (RCA) and LMCA were selected by a radiologist. Reconstructed images were then transferred to a processing workstation for further analysis with specialized software. First, axial resource images and then multiplanar reconstructions were evaluated for all patients.

Degree of stenosis was classified as mild stenosis if it was less than 30%, moderate stenosis if it was between 30% and 50%, and severe stenosis if it was more than 50%, and absence of stenosis is classified as normal. The degree of luminal narrowing was estimated with computer both in MDCT angiography and CA. Estimation was performed with cross-sectional reformatting. The same standardized diagram is used in classification of stenoses for both MDCT and CA stenosis findings.

Statistical Analysis

We rank the clinical findings in Tables 1 and 2 according to the severity of stenosis levels (0 for normal, 1 for mild, 2 for moderate, and 3 for severe stenosis) and compare the severity levels between CA and MDCT in each table with Wilcoxon signed rank test, and severity differences (ranks of CA findings minus MDCT findings in Table 1 and ranks of MDCT findings minus CA findings in Table 2) for both tables were compared with Wilcoxon rank sum test.

In comparing the proportions, Pearson χ^2 tests for proportions are used. In our analysis, we use the statistical software R for windows version 2.2.0 (SPSS for windows 10.0; SPSS Inc., Chicago, Ill). A *P* value less than 0.05 was considered to indicate statistical significance.

We also compare the proportion of agreement in diagnosis between CA and MDCT for both tables to 0 and 1 and with each other. Furthermore, we also compare the

TABLE 1. Catheter Angiography, MDCT Findings, and Consensus Diagnosis About Ostia of Patients Who Were First Evaluated by CA

Coronary Arteries	Patients (n)	CA	MDCT Angiography	Consensus Diagnosis (Cause of Discordance)
RCA (n = 10)	3	Severe stenosis	Moderate stenosis	Moderate stenosis (catheter-induced spasm)
	2	Severe stenosis	Normal	Normal (catheter-induced spasm)
	3	Moderate stenosis	Moderate stenosis	Moderate stenosis
	2	Mild stenosis	Moderate stenosis	Moderate stenosis (positioning of the catheter tip beyond the arterial ostium masked the lesion)
LMCA (n = 9)	3	Severe stenosis (Fig. 1A)	Normal (Fig. 1B)	Normal (catheter-induced spasm)
	2	Severe stenosis	Moderate stenosis	Moderate stenosis (catheter-induced spasm)
	3	Mild stenosis	Mild stenosis	Mild stenosis
	1	Mild stenosis at ostium total occlusion of LAD	Agenesis of LMCA, 2 separate ostia for LCx and LAD, both ostia were normal	Agenesis of LMCA, 2 separate ostia for LCx and LAD, both ostia were normal

LAD indicates left anterior descending artery; LCx, left circumflex artery.

proportion of agreement of CA and MDCT with the criterion standard results for both tables.

RESULTS

In all 33 patients, examinations of coronary arteries were successful, and images were appropriate for evaluation at MDCT and CA. No complication related to the premedication or examination occurred. The MDCT scanning lasted 16 to 24 seconds for each patient.

Finally, 26 patients were diagnosed with aorto-ostial lesion, whereas in 5 patients, aorto-ostial lesions were not present. In 2 patients, anomalous origin of a coronary artery was diagnosed.

When the results were evaluated in terms of the presence of aorto-ostial lesion, MDCT coronary angiography correctly diagnosed all 26 patients, and in the 5 patients with normal ostium, MDCT coronary angiography finding was also normal. However, 7 of 26 patients with aorto-ostial lesion were reported to be healthy by CA, and also 5 patients with normal ostia were reported to have aorto-ostial lesion by CA. Moreover, CA missed the abnormal origination of the coronary arteries in 2 patients.

When the results were evaluated in terms of the degree of the stenosis in 26 patients with aorto-ostial lesion, MDCT

coronary angiography predicted the final diagnosis in all 26 patients correctly. However, CA predicted the final degree of stenosis only in 12 patients. Catheter angiography underestimated the degree of the stenosis in 2 patients, overestimated in 5 patients, and missed the lesion in 7 patients.

Table 1 (group 1) and Table 2 (group 2) show the results of CA, MDCT findings, and the final diagnosis of all patients.

First, notice that in both tables, the angiography method performed first seems to significantly overdiagnose (ie, the diagnosis is more severe for the first method compared with the successive method with $P = 0.0068$ for Table 1 and $P = 0.0088$ for Table 2 by Wilcoxon signed rank test), but this is only a byproduct of the design of our experiment. As described in Materials and Methods section, for 19 patients of Table 1, CA detected stenosis at various levels first, and then, MDCT is applied for comparative purposes. Likewise, for 14 patients of Table 2, MDCT has detected stenosis at various levels first, and then, CA is applied for comparative purposes. However, this seemingly overdiagnosis is not significantly different between Tables 1 and 2 ($P = 0.9834$ by Wilcoxon rank sum test).

In both Tables 1 and 2, the proportion of patients for which CA and MDCT agree in diagnosis is significantly

TABLE 2. Multidetector CT, CA Findings, and Consensus Diagnosis About Ostia of Patients Who Were First Evaluated by MDCT

Coronary Arteries	Patients (n)	MDCT Angiography	CA	Consensus Diagnosis (Cause of Discordance)
RCA (n = 9)	3	Moderate stenosis (Figs. 2A, B)	Normal (Fig. 2C)	Moderate stenosis (positioning of the catheter tip beyond the arterial ostium masked the lesion)
	2	Mild stenosis	Normal	Mild stenosis (positioning of the catheter tip beyond the arterial ostium masked the lesion)
	2	Moderate stenosis	Moderate stenosis	Moderate stenosis
	1	Severe stenosis	Severe stenosis	Severe stenosis
	1	Anomalous origination of RCA from LAD	RCA could not visualized Aberrant vessel originating from LAD	Anomalous origination of RCA from LAD
LMCA (n = 5)	2	Moderate stenosis	Normal	Moderate stenosis (positioning of the catheter tip beyond the arterial ostium masked the lesion)
	3	Mild stenosis	Mild stenosis	Mild stenosis

LAD indicates left anterior descending artery; LCx, left circumflex artery; RPD, right posterior descending artery.

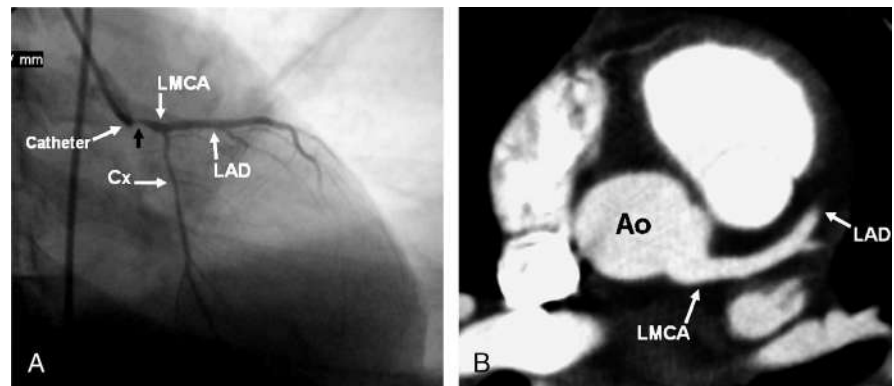


FIGURE 1. A, Catheter angiogram shows the severe stenosis at ostium of LMCA. B, In the same patient axial enhanced MIP image of MDCT, coronary angiography shows the normal LMCA ostium. LAD indicates left anterior descending artery; Ao, Aorta; Cx, Circumflex artery.

larger than 0 and significantly smaller than 1 for overall (RCA and LMCA combined), RCA, and LMCA separately ($P < 0.0001$ for each test). That is, there is considerable agreement between CA and MDCT in diagnosing stenosis, but disagreement is significantly larger (except for LMCA in Table 2).

In terms of agreement with the criterion standard, in Table 1, MDCT has perfect agreement with the criterion standard, whereas the proportion of agreement of CA with criterion standard is significantly less for overall ($P < 0.0001$), RCA ($P = 0.0025$), and LMCA ($P = 0.0035$). On the other hand, in Table 2, MDCT has perfect agreement with the criterion standard, whereas the proportion of agreement of CA with criterion standard is significantly less for overall ($P = 0.0040$), for RCA ($P = 0.0155$), but not for LMCA ($P = 0.2146$). Therefore, the performance of MDCT is significantly better than CA in terms of diagnosis agreement with the criterion standard.

DISCUSSION

Aorto-ostial lesions occur within the first 3 mm of the coronary artery, as it splits from the aorta.² Because of the

complications associated with aorto-ostial lesions, diagnosis and treatment are crucial.

Although CA is the criterion standard for diagnosing coronary artery disease, it has some important technical restrictions in visualization of the aorto-ostial lesions.^{10,11} Aorto-ostial lesions are most likely to be associated with suboptimal angiographic results due to lesion rigidity, catheter-induced spasm, anomalous origination of the coronary arteries, or positioning of the catheter tip beyond the arterial ostium.^{10,11} Furthermore, CA provides only a 2-dimensional view of a vessel's complex 3D path, so the anatomical course of the anomalous vessels with respect to the aorta and pulmonary artery may be difficult to discern.¹²

Current studies indicate that MDCT is a reliable technique for imaging the coronary arteries. Some studies suggested that MDCT is more reliable in detection of lesions in proximal coronary arteries compared with those more distal segments.¹²⁻¹⁶

To our knowledge, there is no study evaluating the use of MDCT in detection of aorto-ostial lesions. Depending on very limited data, Aviram et al¹⁷ and Gurevitch et al¹⁸ suggested that aorto-ostial lesions can be visualized well with MDCT. Our study is the first to compare MDCT coronary

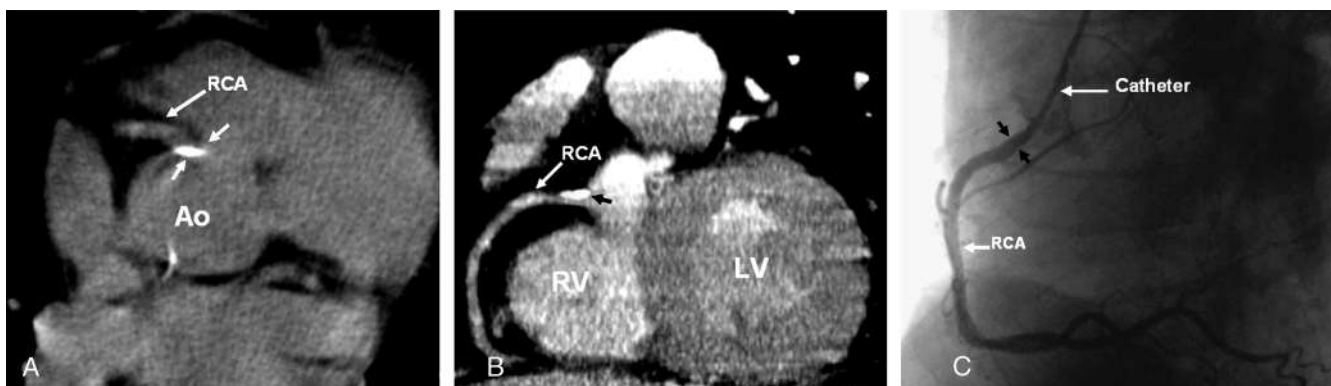


FIGURE 2. A, Axial unenhanced calcium scoring image, obtained by MDCT, shows calcific, discrete plaque in the ostium of RCA. B, Sagittal enhanced MIP image of MDCT coronary angiography shows calcific plaque producing moderate stenosis in ostium of RCA (black arrow). C, Catheter angiography fails to show the ostial stenosis because of the positioning of the catheter tip beyond the lesion. RV indicates right ventricle; LV, left ventricle; black arrows, tip of catheter.

angiography and CA in visualization of aorto-ostial lesions. In this article, we demonstrate that MDCT coronary angiography does not experience the above-mentioned flaws present in the use of CA for aorto-ostial lesions.

In all patients, the MDCT findings were the same as the consensus diagnosis.

Aorto-ostial stenosis, especially if it is not severe, may be missed by CA because the catheter tip may be positioned beyond the lesion.¹⁸ For example, in our study CA missed the lesion in 7 of the 26 patients because of this incorrect positioning. As the most proximal parts to the aorta of the coronary arteries can be visualized well by MDCT coronary angiography, a coronary CA may not be required.

Catheter-induced spasm is an important complication false diagnosis of coronary stenosis by CA. Although this spasm can be dissolved by nitroglycerine (Perlinganite; Orion Pharma, Turku, Finland) infusion,¹⁹ sometimes the occurrence of a spasm can falsely be diagnosed as a lesion, as in 5 patients in our study who were found to be healthy by MDCT. Hence, in patients who were diagnosed with aorto-ostial lesion by CA, performing MDCT may be useful in preventing the false diagnosis due to catheter-induced spasms.

Because of the selective catheterization of coronary arteries, origination of LAD and Cx from different ostia may falsely be identified as total occlusion of the vessel in CA. In these patients, MDCT can provide more accurate diagnoses because 3D volume-rendered images make it possible to visualize the aberrant ostia and adjacent normal ostia of coronary arteries. Furthermore, with 3D images of coronary arteries, abnormal origination of a coronary artery from the other one can best be visualized as in one of our cases (Table 2).

Limitations in Our Study

1. In all patients, the MDCT studies were done in optimal conditions, so the images were good for evaluation. However, it may not be possible to obtain such good results in every patient, so it may result in false-negative or false-positive results.
2. Although the radiologist and the cardiologist did not know the localization and degree of the lesion, both were aware of the presence of aorto-ostial lesions. This might influence our findings, as it constitutes a bias in our study. But as this bias factor is present for both CA and MDCT analysis, its influence can be assumed to be negligible for comparative purposes.
3. We do not have an objective criterion standard to compare the findings of MDCT and CA. Hence, although subjective, we had to set the mutual diagnosis by the radiologist and the cardiologist as our criterion standard which was the final diagnosis made by the consensus of the radiologist and cardiologist.

In conclusion, our findings suggest that MDCT is a reliable diagnostic tool for diagnosing the presence and severity of aorto-ostial lesions. In addition, MDCT might be useful in preventing the false diagnosis due to the catheter-induced

spasms in patients who were diagnosed with aorto-ostial lesion by CA. Moreover, if MDCT coronary angiography detects a lesion in aorto-ostial region, where MDCT is quite sensitive, there is no need to perform CA to merely verify this pathology. Because positioning of the catheter tip beyond the arterial ostium may mask the lesion, which in turn might yield a false finding.

REFERENCES

1. Hoffmann HK, Shi H, Schmid FT, et al. Noninvasive coronary imaging with MDCT in comparison to invasive conventional coronary angiography. A fast-developing technology. *AJR Am J Roentgenol*. 2004;182:601–608.
2. Braunwald E. Coronary angiography and intravascular ultrasound imaging. In: Braunwald E, ed. *Heart disease: a textbook of cardiovascular medicine*, 6th ed. Philadelphia, PA: Saunders; 2001: 496–497.
3. Schoepf UJ, Becker CR, Hofmann LK, et al. Multidetector-row CT of the heart. *Radiol Clin North Am*. 2003;41:491–505.
4. Ropers D, Baum U, Pohle K, et al. Detection of coronary artery stenoses with thin-slice multi-detector row spiral computed tomography and multiplanar reconstruction. *Circulation*. 2003;107:664–666.
5. Nieman K, Rensing BJ, van Geuns RJ, et al. Usefulness of multislice computed tomography for detecting obstructive coronary artery disease. *Am J Cardiol*. 2002;89:913–918.
6. Kopp AF, Schroeder S, Kuettner A, et al. Non-invasive coronary angiography with high resolution multidetector-row computed tomography: results in 102 patients. *Eur Heart J*. 2002;23: 1714–1725.
7. Amoroso G, Battolla L, Gemignani C, et al. Myocardial bridging on left anterior descending coronary artery evaluated by multidetector computed tomography. *Int J Cardiol*. 2004;95:335–337.
8. Kachelriess M, Ulzheimer S, Kalender WA. ECG-correlated image reconstruction from subsecond multi-slice spiral CT scans of the heart. *Med Phys*. 2000;27:1881–1902.
9. McCollough CH, Zink FE. Performance evaluation of a multi-slice CT system. *Med Phys*. 1999;26:2223–2230.
10. Chin K. An approach to ostial lesion management. *Curr Interv Cardiol Rep*. 2001;3:87–89.
11. Toutouzas K, Stankovic G, Takagi T, et al. Outcome of treatment of aorto-ostial lesions involving the right coronary artery or a saphenous vein graft with a polytetrafluoroethylene-covered stent. *Am J Cardiol*. 2002;90:63–66.
12. Shi H, Aschoff AJ, Brambs HS, et al. Multislice CT imaging of anomalous coronary arteries. *Eur Radiol*. 2004;14:2172–2181.
13. Datta J, White CS, Gilkeson RC, et al. Anomalous coronary arteries in adults: depiction at multi-detector row CT angiography. *Radiology*. 2005;235:812–818.
14. Schoenhagen P, Halliburton SS, Stillman AE, et al. Noninvasive imaging of coronary arteries: current and future role of multi-detector row CT. *Radiology*. 2004;232:7–17.
15. Hague C, Andrews G, Forster B. MDCT of a malignant anomalous right coronary artery. *AJR Am J Roentgenol*. 2004;182:617–618.
16. Lawler LP, Pannu HK, Fishman EK. MDCT evaluation of the coronary arteries, 2004: how we do it—data acquisition, postprocessing, display, and interpretation. *AJR Am J Roentgenol*. 2005;184: 1402–1412.
17. Aviram G, Finkelstein A, Herz I, et al. Clinical value of 16-slice multi-detector CT compared to invasive coronary angiography. *Int J Cardiovasc Intervent*. 2005;7:21–28.
18. Gurevitch J, Gaspar T, Orlov B, et al. Noninvasive evaluation of arterial grafts with newly released multidetector computed tomography. *Ann Thorac Surg*. 2003;76:1523–1527.
19. Bossert T, Bittner HB, Gummert JF, et al. Coronary artery spasm of the native right coronary artery during off-pump coronary surgery of the left coronary artery system. *Clin Res Cardiol*. 2006;95:115–118.