

# A Radiological Study on the Topographical Relationships between the Vestibular, Cochlear and Facial Nerves

## *Vestibuler, Koklear ve Fasiyal Sinirin Topografik İlişkileri: Radyolojik Bir Çalışma*

Sacide Unel<sup>1</sup>, Mehmet Yılmaz<sup>2</sup>, Sait Albayram<sup>3</sup>, Adem Kiris<sup>1</sup>, Zehra Isik<sup>3</sup>, Elvan Ceyhan<sup>4</sup>, Huseyin Isildak<sup>5</sup>, Yildiray Savas<sup>1</sup>, Zafer Keser<sup>6</sup>

<sup>1</sup>Department of Radiology, Haseki Training and Research Hospital, Istanbul, Turkey

<sup>2</sup>Department of Otorhinolaryngology, Cerrahpasa Faculty of Medicine, Istanbul University, Istanbul, Turkey

<sup>3</sup>Department of Radiology, Cerrahpasa Faculty of Medicine, Istanbul University, Istanbul, Turkey

<sup>4</sup>Department of Mathematics, Koc University, Istanbul, Turkey

<sup>5</sup>Christiana Case Health System, Newark, DE, USA

<sup>6</sup>Cerrahpasa Faculty of Medicine, Istanbul University, Istanbul, Turkey

### Abstract

**Objective:** The purpose of our study was to investigate the topographical relationship between these nerves along their course from the brainstem through the internal acoustic canal IAC in the living human brain using MR imaging.

**Materials and Methods:** We performed three-dimensional gradient echo balanced Fast Field Echo (3D bFFE) sequence oblique parasagittal MR imaging in 73 healthy subjects. The IACs were analyzed from the brainstem end of the IAC to the fundus in contiguous sections. At five levels, the topographical relationships between the facial and vestibulocochlear nerves (VCN) were recorded. In the lateral portions of the IACs where they separated from each other, the relative sizes of the individual nerves were examined.

**Results:** In general, the facial nerve (FN), which is a round structure, is located anteriorly and superiorly to the vestibulocochlear nerve throughout its course. The vestibulocochlear nerve is usually rectangular; however, it was found to be round and at times triangular in shape near the brainstem, before it became crescent-shaped at the porus in 89% of the cases. The superior vestibular nerve kept its posterosuperior position in the canal, and the inferior vestibular nerve (IVN) and the cochlear nerve (CN) travelled inferior to it. The superior and inferior vestibular nerves were divided by the falciform crest in 53% of the cases. The inferior vestibular nerve was the smallest nerve in 52% of the cases, and the cochlear nerve was the largest in 36% of the cases.

**Conclusion:** To the best of our knowledge, this study is the largest in vivo MR study, and most of our findings differ from previous cadaver studies. Determination of these topographical relationships may facilitate our understanding of the complicated physiological relationships between the 7<sup>th</sup> and 8<sup>th</sup> nerve complexes during surgery in this region.

**Key Words:** Cochlear nerve, Facial nerve, Magnetic Resonance, Topography, Vestibular nerve

### Özet

**Amaç:** Bizim amacımız, yaşayan insanlarda MR görüntülemeyi kullanarak, bu sinirlerin beyin sapından, internal akustik kanala kadar olan kısmında topografik ilişkilerini araştırmaktır.

**Gereç ve Yöntem:** Yetmiş üç sağlıklı bireyde 3D gradient echo balanced fast field echo (3D bFFE) sekans oblik parasagittal MR inceleme yaptık. İAK, beyin sapından İAK'ın bitimindeki fundusa kadar, ardışık kesitlerle analiz edildi. Beş seviyede fasiyal ve vestibulokoklear sinirin topografik ilişkileri kaydedildi. İAK'ın lateral bölümünde (sinirin kendi içinde bölümlere ayrıldığı kısımda) sinirlerin rölatif boyutları değerlendirildi.

**Bulgular:** Genel olarak fasiyal sinir, yuvarlak bir yapıda, anterior yerleşimli ve tüm seyri boyunca vestibulokoklear sinirin süperiorundadır. Vestibulokoklear sinir ıklıkla dikdörtgen şeklindedir. Fakat bazen beyin sapına yakın kısımda yuvarlak ve nadiren üçgen şeklinde ve vakaların %89'unda porusda kresentrik yapıdadır. Superior vestibuler sinir kanal içinde posterosüperior pozisyonunu korur ve inferior vestibüler sinir ve koklear sinir superior vestibüler sinirin altından geçer. Süperior ve inferior vestibüler sinirler vakaların %53'ünde falsiform krest tarafından bölünür. İnförior vestibüler sinir vakaların %52'sinde en küçük, koklear sinir vakaların %36'sında en geniş olarak izlenmiştir.

**Sonuç:** Bildiğimiz kadarıyla, bu en büyük in vivo MR çalışması olup, bulgularımızın çoğu önceki kadavra çalışmalarından farklıdır.

**Anahtar Kelimeler:** Koklear sinir, Fasiyal sinir, Manyetik Rezonans, Topografya, Vestibüler sinir

**Received:** October 10, 2011 / **Accepted:** December 01, 2011

**Correspondence to:** Mehmet Yılmaz, Department of Otorhinolaryngology, Cerrahpasa Faculty of Medicine, Istanbul University, Istanbul, Turkey  
Phone: +90 505 234 98 13 e-mail: drmofly@yahoo.com

doi:10.5152/eajm.2012.02

## Introduction

Along their course from the brainstem to the internal acoustic canal, the relationship between the facial and vestibulocochlear nerves shows some variations [1, 2]. With the development of microsurgery and endoscopic surgery in the internal acoustic canal (IAC), the study of the topographical relationship between these two nerves in the human IAC becomes increasingly important for the diagnosis and surgical planning of acoustic schwannomas [2-4]. Additionally, depictions of cochlear nerve integrity may be important for diagnosis and management of sensorineural hearing loss [5].

Previously, detailed anatomical studies of these nerves have mainly been performed in cadavers. Cadaver studies always carry the risk that the anatomical relationships and shapes of the component of the nerves in the IAC and cerebellopontine cisterns may have been altered due to the absence of cerebellopontine fluid and blood supply as well as the formalin fixation, which results in the shrinkage of nerves [3-7]. Therefore, anatomical studies must be conducted in living human tissue to define the true anatomical relationships among these nerves within the IAC and cerebellopontine cistern [3].

Our purpose was to investigate the topographical relationships and shapes of the facial and vestibulocochlear nerves along their course from the brainstem through the IAC as well as examine the relative sizes of the nerves in the lateral portion of the IAC in the living human brain by using magnetic resonance (MR) imaging.

## Materials and Methods

We examined 138 ears of 73 volunteers (43 females and 30 males; age range 10-77 years, mean age 43 years). The magnetic resonance imaging (MRI) examinations had been performed for other indications. Eight canals were excluded from the study due to either the blurring of the images secondary to motion artifacts or because some canals were too narrow to allow precise identification of the nerves at all levels. The 3D Balanced Fast Field Echo (3D bFFE) images were added as an additional sequence. Informed consent was obtained from all patients, and approval for the project was obtained from the Human Subject Committee. No subjects had symptoms or signs relating to these nerves.

A 1.5 Tesla superconducting magnet (Philips Achieva, Best, The Netherlands) with standard 8-channel head coil was used. MRI cisternography of oblique parasagittal sections perpendicular to the IAC were acquired using a 3D balanced fast field echo (3D b FFE) sequence with the following parameters: 500/120 (TR / TE), 1024x1024 matrix (256-echo train length), NEX: 2, 100x124 mm field of view, 1.5 mm slice thickness (with 0.5 mm gap) and 5 minute 59 second acquisition time.

Along their course from the brainstem to the fundus, the shapes of the nerves and the relationships between the nerves were investigated at the following five levels: near the brainstem, at the mid-point between the brainstem and the porus acousticus, at the porus acousticus, at the mid-point of the IAC, and at the lateral portion of the IAC.

We also examined the relative sizes of the nerves in the lateral portion of the IAC, where they separated from each other, and the degree of symmetry of the two IACs within an individual.

## Results

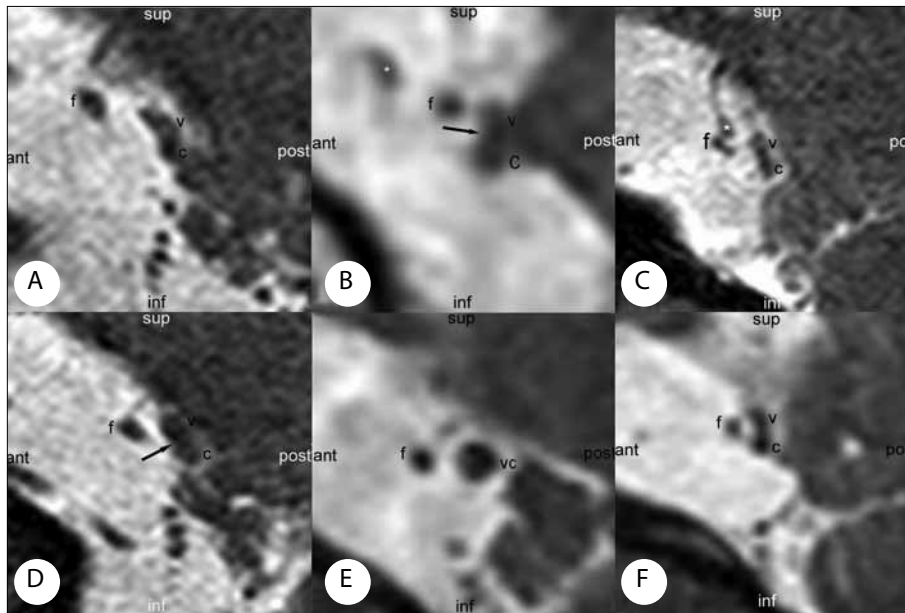
Near the brainstem, the facial nerve was located antero-superiorly to the vestibulocochlear nerve complex in 56 ears (40%) (Figure 1a, 1b), whereas it was located anterior to the superior portion of the vestibulocochlear nerve complex in 37 ears (27%) (Figure 1b-1d) and it was located anterior to the vestibulocochlear nerve complex in 44 ears (32%) (Figure 1e, 1f). The cross-sectional shape of the vestibulocochlear nerve complex was rectangular in 83 ears (60%) (Figure 1c), round in 41 ears (30%) (Figure 1e) and crescent-shaped in 9% ears (Figure 1a, 1f). In most of the rectangular or crescent-shaped vestibulocochlear nerve complexes, the cochlear and vestibular nerves were partially identified by a hyperintense zone or a groove between the two components (Figure 1b, 1d, 1f).

At the midpoint between the brainstem and the porus acousticus, the FN was located anteriorly to the VCN complex in only 23 ears (16%), whereas it was located anterosuperiorly (Figure 2a-2d) or anteriorly to the superior portion of the VCN complex in the remaining cases (Figure 2e). In this segment, 41% of rectangular or round-shaped vestibulocochlear nerve complexes changed to a curved shape (Figure 2f).

At the porus acousticus, the facial nerve and the vestibulocochlear nerve complex occupied the inferior portion of the IAC in 45% of the cases (62 ears); however, the facial nerve kept its position anterosuperior or anterior to the superior portion of the VCN complex in 97 of the ears (70%). The VCN complex was crescent-shaped in 123 ears (89%) (Figure 3a, 3b). The three components of the VCN complex were identified as rounded enlargements of the nerve complex in 78% of the ears (Figure 3c).

At the mid-point between the porus acousticus and the fundus, the facial nerve occupied the anterosuperior portion of the canal in 90% of the ears. The cochlear nerve was separated from the complex in 43% of the ears (Figure 4a), and all three components of the VCN complex were separate in 11% of the ears (Figure 4b). In 6 ears, the SVN was separate while CN and IVN were still held together.

In the lateral portion of the IAC, the facial nerve was in the anterosuperior portion of the canal in 93% of the ears.



**Figure 1.** A) The VCN is rectangular in shape while the FN is anterosuperior to the slightly curved-shaped VCN in the other ear, B) Near the brainstem, the VCN is rectangular in shape and has a shallow groove, and the FN is located anterior to the Groove, C) Near the brainstem, the FN is located anteriorly to the superior portion of the VCN. The VCN in the cross-sectional is rectangular in shape D) Near the brainstem, the FN is located anteriorly to the superior portion of the VCN, E) Near the brainstem, the FN is located anteriorly to the VCN. The VCN is round in the cross-sectional, F) The VCN is slightly curved with a groove, and the FN is anterior to the groove near the brainstem.

(Asterisks: vascular structure, F=FN; C= CN; S= SVN; I= IVN; ant= anterior; post= posterior; sup=superior; inf=inferior). b-e, the right ear; a and f, the left ear

The 1.5 mm-thick oblique parasagittal 3D b FFE images show the topographical relationship between the facial and vestibulocochlear nerves.

In 6 ears, the facial nerve and the superior vestibular nerve could not be separated from each other, and together they were located at the superior portion of the canal (Figure 5a). The cochlear nerve was traveling on its own in all of the examined ears and occupied the anteroinferior (SVN) portion of the IAC. The superior and inferior vestibular nerves were completely separate from the complex only immediately prior to the transverse crest in 78% of the ears (Figure 5b).

The topographical relationships between the nerves in the cerebellopontine cistern and IAC are summarized in Table 1.

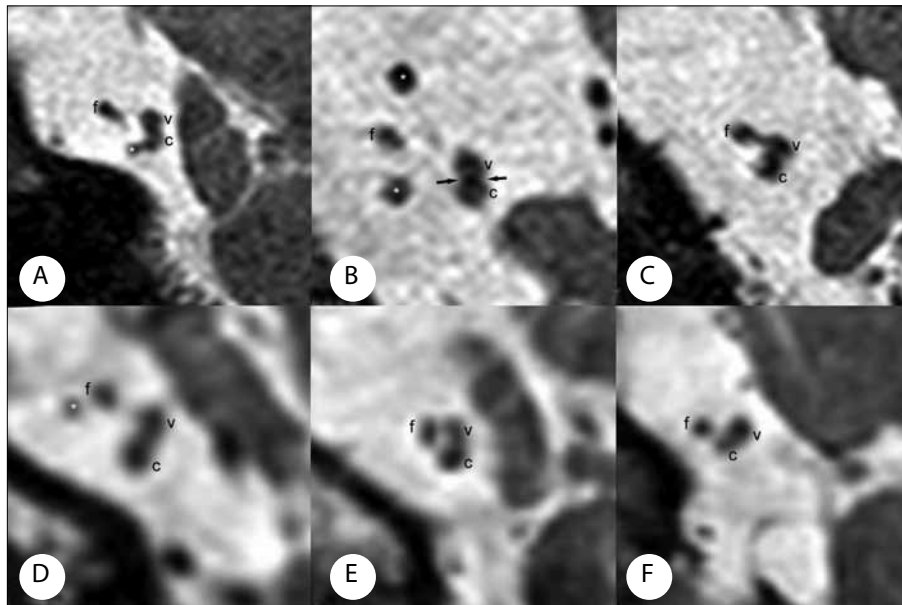
In the lateral portion of the IAC, where the nerves separated from each other, the cochlear and the facial nerves were similar in size and comprised the largest nerves in 48% of the ears (Figure 5c). The cochlear nerve was the largest nerve in 34% of the ears (Figure 5b). The superior and inferior vestibular nerves (VN) were similar in size in 46% of the ears. The facial, cochlear and superior vestibular nerves were smooth and round in shape in most of the cases. The IVN was the smallest component of the vestibulocochlear nerve complex and was in general irregularly shaped. The relative sizes of the nerves were symmetrical in both IACs in 45% of the paired ears (Table 2).

In 65 individuals, the two IACs were compared regarding the topographic relationships and shapes of the nerves as well as their relative sizes within the lateral portion of the IAC. In only one individual, the two IACs were symmetrical at all five levels. In 10% of the cases, there was no symmetry between the two IACs at any level.

## Discussion

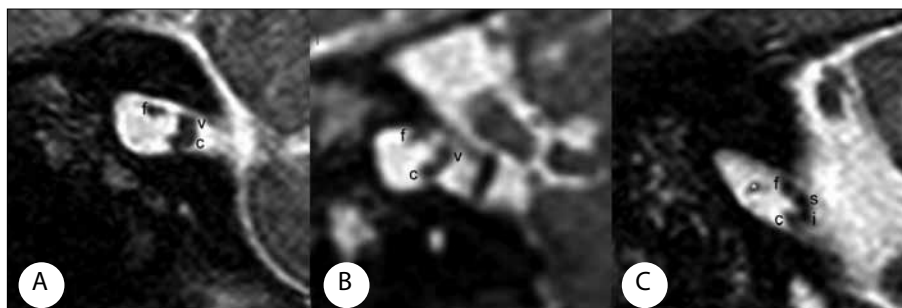
The anatomy of the neural structures in the IAC has been the subject of numerous histological, surgical and radiological investigations owing to its clinical and functional importance [1-4, 7].

MRI studies have shown that the facial nerve is located anteriorly to the vestibulocochlear nerve and, as the nerve travels laterally in the IAC, its position changes to anterosuperior to the vestibulo-cochlear nerve [6]. Using MRI, Kim et al. observed a posteroinferior displacement of the facial and vestibulocochlear nerves in the IAC [4]. The facial nerve occupied the anterosuperior portion of the canal in 11 cases (37%), and the facial nerve rotated anteroinferiorly from the



**Figure 2.** A) At the mid-point between the brainstem and the porus acusticus, the VCN is rectangular, and the VN and CN can be identified by a slightly hyperintense zone between them, B) The FN was located anteriorly to the VCN complex, and it was located anterosuperiorly in the remaining cases, C) The FN was located anteriorly to the VCN complex, and it was located anterosuperiorly in the remaining cases, D) At the mid-point between the brainstem and the porus acusticus, the VCN is rectangular in shape and has a shallow groove, and the FN is located anterior to the groove, E) The FN was moved slightly superiorly at the mid-point between the brainstem and the porus acusticus, F) At the mid-point of the brainstem, the VCN is slightly curved in shape, and the FN is anterior to the VCN  
A, C, D, and F, the right ear; B and E, the left ear.  
The abbreviations are the same as in Figure 1

The 1.5 mm-thick oblique parasagittal 3D bFFE images show the topographical relationship between the facial and vestibulocochlear nerves.



**Figure 3.** A) At the porus acusticus, the VCN becomes curved and occupies the posterior portion of the IAC. The FN is located anterosuperiorly to the VCN, B) The VCN complex was crescent-shaped, C) The three components of the VCN complex were identified as rounded enlargements of the nerve complex in 78% of the ears.  
The abbreviations are the same as in Figure 1






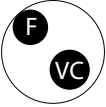
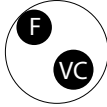



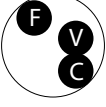
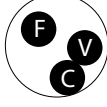





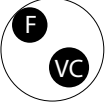


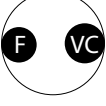
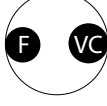


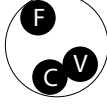

The 1.5 mm-thick oblique parasagittal 3D bFFE images show the topographical relationship between the facial and vestibulocochlear nerves.

bottom of the IAC to the porus acusticus in 19 cases (63%). Therefore, the facial nerve is located in the anteroinferior or anterior portion in the porus acusticus [2].

In the present study, we observed that the FN is located anteriorly and superiorly to the vestibulocochlear nerve

throughout its course from the fundus to the brainstem. Although in some cases the distance between the FN and the VCN was narrowed, when they coursed medially through the IAC in 70% of the 138 examined ears, the FN kept its position anterosuperior to the VCN at the porus acusticus. The FN

**Table 1. The topographical relationships between the nerves in the cerebellopontine cistern and IAC**

Near the brain stem	Intercisternal segment	Porus Acousticus	Mid portion of the IAC	Lateral portion of the IAC
 37 ears 27%	 41 ears 30%	 30 ears 22% <sup>+</sup>	 54 ears 39%	 66 ears 48%
 31 ears 22%	 21 ears 15%	 23 ears 17% <sup>++</sup>	 8 ears 6%	 51 ears 37%
 25 ears 18%	 44 ears 32%	 50 ears 36% <sup>+++</sup>	 59 ears 43%	 14 ears 10% <sup>#</sup>
 33 ears 24% <sup>*</sup>	 20 ears 14%	 3 ears 2%	 6 ears 4%	 7 ears 5% <sup>##</sup>
 12 ears 9%	 3 ears 2%	 32 ears 23% <sup>++++</sup>	 6 ears 4%	
	 9 ears 7% <sup>°</sup>		 5 ears 4%	

F=FN, VC=VCN, S= SVN, I= IVN, C= CN

\*FS occupies the anterosuperior portion of the canal in one ear.

°FS occupies the superior portion of the canal in one ear

+FS locates superior to the VCN in 9 ears, ++In 7 ears, the VKS occupies the posteroinferior portion of the canal, +++In 5 ears, the VKS occupies the posteroinferior of the canal, ++++FS locates anteroinferior to the VCN in 2 ears.

#In 6 ears, the FS and SVS are inseparable from each other and located at the superior portion of the canal. ##FS locates superior to the VCN in 4 ears

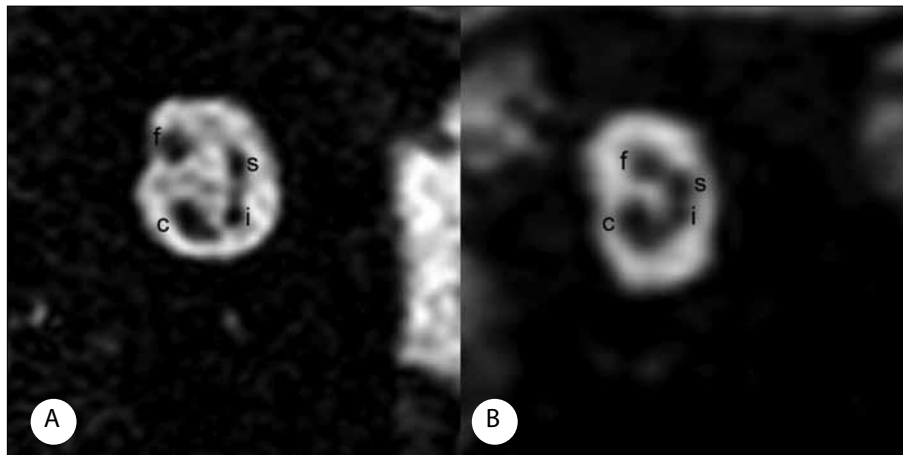
was located anterosuperiorly or anteriorly to the superior portion of the VCN near the brainstem in 67% of the ears.

Ozdogmus et al. showed that the vestibular, cochlear and facial nerve bundles did not have a straightforward course

within the IAC [1]. A counterclockwise rotation of the nerves was observed in the right ear from the end of the inner ear to the end of the brainstem and the reverse was observed in the left ear. Tian et al. dissected 30 temporal bones of 15 heads

**Table 2. The relative sizes of the nerves in the lateral portion of the IAC**

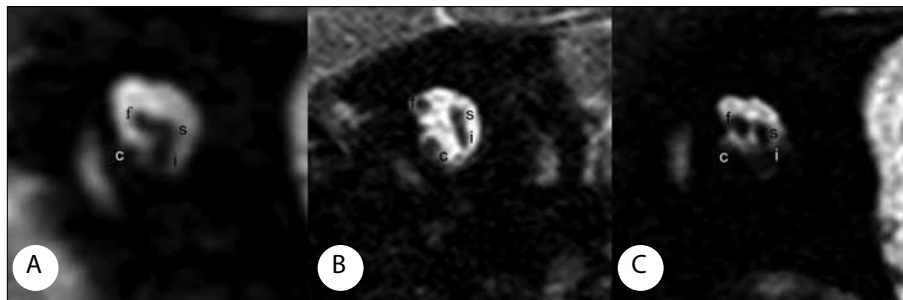
Pattern	K>F>Vs≥Vi	F=K=Vs≥Vi	F=K>Vs≥Vi	F>K=Vs>Vi	F>K>Vs≥Vi	K>Vs=Vi>F	Vs>K>F>Vi
n	46	37	29	10	3	3	10
%	34*	27*	21*	7	2*	2	7
*Vi=Vs in 46% of the ears							



**Figure 4.** A) In the left ear, the IVN and SVN are similarly sized at the mid-point of the IAC, B) At the mid-point of the IAC, the VCN is crescent-shaped and located in the inferior and posterior portion of the IAC a and b, the left ear.

The abbreviations are the same as in Figure 1.

The 1.5 mm-thick oblique parasagittal 3D b FFE images show the topographical relationship between the facial and vestibulocochlear nerves.



**Figure 5.** A) In the lateral portion of the IAC, the CN is separated from the VCN complex, B) In the lateral portion of the IAC, the CN is separated from the VCN complex, C) In the lateral portion of the IAC (e), the CN and FN are similar in size and larger than the SVN; the IVN is the smallest nerve

The abbreviations are the same as in Figure 1.

The 1.5 mm-thick oblique parasagittal 3D b FFE images show the topographical relationship between the facial and vestibulocochlear nerves.

and reported that the nerves rotated counterclockwise in the right ear and clockwise in the left ear along their course from the inner ear to the end of the brainstem [2]. An MRI study by Ryu et al. also showed spatial changes of the nerves of the IAC, reporting that the inferior vestibular and the cochlear nerves passed below the superior vestibular nerve rather than rotating toward the brainstem [3].

We revealed that the SVN keeps its position throughout its course in the IAC and cerebellopontine cistern; however, the IVN moved farther superiorly through the brainstem, and the CN moved farther posterior. Our findings are in agreement with a previous MRI study reported by Ryu et al. but differ from previous cadaver studies. We believe this is due to the distortion of the normal spatial relationships in the

absence of cerebrospinal fluid and blood supply as well as the shrinkage of the nerves through formalin fixation and the displacement of the nerves that may have occurred during harvesting of the specimens [1, 3, 7].

The present study shows that near the brainstem the VCN is most frequently rectangular (60%) or round (31%) in shape but that it changes into a crescent shape in the cerebellopontine cistern when approaching the porus acousticus (89%). Kim et al. observed the cross-section of the VCN to be rectangular or crescent-shaped near the brainstem while Mitsuoka et al. reported a round-shaped VCN near the brainstem.

Previous studies have described similar sized vestibulocochlear nerves within an individual but no data are available regarding the relative sizes or symmetry of the four nerves in the lateral portion of the IAC [4, 7].

In the lateral portion of the CN, the largest part of the VCN was found in 93% of the ears, and the IVN was found to be the smallest component of the complex. We identified 7 different patterns of relative sizes of the nerves and our findings are similar to those reported by Kim et al., who first reported on these findings.

The anatomy within the internal acoustic canal differs from individual to individual, but limited data suggest symmetry of the anatomy of the canals within individuals [7]. In the present study, the relative sizes of the nerves were symmetrical within an individual in only 45% of the cases. The symmetry of the relationships between the nerves is mostly observed in the lateral portion of the canal (57%) followed by the porus (48%) and is found to be less frequent than reported in previous studies [4].

In conclusion, to our knowledge, this is the largest in vivo MRI study and most of our results differ from previous

cadaver and MRI studies. Determination of these topographical relationships may facilitate our understanding of the complicated physiological relationships between the 7<sup>th</sup> and 8<sup>th</sup> nerve complexes during surgery in this region.

**Conflict of interest statement:** The authors declare that they have no conflict of interest to the publication of this article.

## References

1. Özdogmus Ö, Sezen O, Kubilay U, et al. Connections between the facial, vestibular and cochlear nerve bundles within the internal auditory canal. *J Anat* 2004; 205: 65-75. [\[CrossRef\]](#)
2. Tian G, Huang D, Liao H, Huang M. The topographical relationships and anastomosis of the nerves in the human internal auditory canal. *Surg Radiol. Anat* 2008; 30: 243-7. [\[CrossRef\]](#)
3. Ryu H, Tanaka T, Ymamoto S, Uemura K, Takehara Y, Isoda H. Magnetic resonance cisternography used to determine precise topography of the facial nerve and three components of the eighth cranial nerve in the internal auditory canal and cerebellopontine cistern. *J Neurosurg* 1999; 90: 624-34. [\[CrossRef\]](#)
4. Kim HS, Kim D, Chung H, Lee WS, Kim KY. Topographical relationship of the facial and vestibulocochlear nerves in the subarachnoid space and internal auditory canal. *AJNR Am J Neuroradiol* 1998; 19: 1155-61.
5. CM Davidson HC, Harnsberger HR, Butler J, Kertesz TR, Shelton C. Imaging findings of cochlear nerve deficiency. *AJNR Am J Neuroradiol* 2002; 23: 635-43.
6. Mitsuoka H, Arai H, Tsunoda A, Okuda O, Sato K, Makita J. Microanatomy of the cerebellopontine angle and internal auditory canal: study with new magnetic resonance imaging technique using three-dimensional fast spin echo. *Neurosurgery* 1999; 44: 561-7. [\[CrossRef\]](#)
7. Rubinstein D, Sandberg EJ, Cajade-Law AG. Anatomy of the facial and vestibulocochlear nerves in the internal auditory canal. *AJNR Am J Neuroradiol* 1996; 17: 1099-105.