AVIAN DISEASES 45:70–75, 2001

Characterization of Mycoplasma gallisepticum Infection in Captive House Finches (Carpodacus mexicanus) in 1998

Sharon R. Roberts, Paul M. Nolan, and Geoffrey E. Hill

Department of Biological Sciences, Auburn University, AL 36849

Received 22 May 2000

SUMMARY. Since 1995, the epidemic of mycoplasmal conjunctivitis in eastern house finches has affected the Auburn, AL, house finch population. To better characterize the current status of this host–parasite interaction, we established a captive flock of 38 seronegative, healthy finches in fall 1998. After a minimum quarantine period of 4 wk, two *Mycoplasma gallisepticum* (MG)-infected house finches were introduced into this flock. Over a 12-wk period, the flock was captured every 2 wk and each bird was observed for conjunctivitis. Blood and choanal swabs were collected from each bird for serologic analysis and for the detection of MG by polymerase chain reaction. The infection spread rapidly through the flock just as it had in a similar study performed in 1996 at the height of the epidemic. Unlike the earlier study in which birds remained chronically infected, most of the birds in our study recovered rapidly, and only three of the birds died during the study. Two patterns of host response to infection with MG were observed. Twenty-seven birds (73%) experienced an acute conjunctivitis that resolved, and the birds appeared to clear the infection. Ten birds (27%) suffered prolonged clinical disease, and MG could be detected in these birds intermittently throughout the experiment. These results, in conjunction with our surveys of MG in the wild population, suggest an evolving host–parasite interaction.

RESUMEN. Características de la infección por Mycoplasma gallisepticum en frailecillos o gorriones (Capodacus mexicanus) on cautiverio en 1998.

Desde 1995 una conjuntivitis causada por *Mycoplasma* en los frailecillos ó gorriones (*Capodacus mexicanus*) del este ha afectado la población de frailecillos en Auburn, Alabama. Con el fin de entender mejor la relación húesped parásito se estableció una parvada de 38 frailecillos sanos en cautiverio en el otoño de 1998. Después de un período de cuarentena de 4 semanas se introdujeron a la parvada dos frailecillos infectados con *Mycoplasma gallisepticum*. Durante un período de 12 semanas la parvada fue capturada cada dos semanas y se observó cada ave para la presencia de conjuntivitis. Se tomaron muestras de sangre e hisopos coanales para análisis serológico y detección de *M. gallisepticum* por medio de la reacción en cadena por la polimerasa. La infección se propagó rápidamente a través de toda la parvada de manera similar a como se habia propagado en un estudio realizado durante una epidemia ocurrida en 1996. A diferencia de este estudio temprano donde las aves permanecieron infectadas crónicamente las aves de este estudio se recuperaron rápidamente y sólamente tres de ellas murieron. Se observaron dos patrones de respuesta a la infección de M. gallisaepticum. Se observó una conjunctivitis aguda en 27 aves (73%) de la cual las aves se recuperaron. Diez aves sufrieron una enfermedad crónica y el *M. gallisepticum* se pudo detectar en estas aves de forma intermitente a través del experimento. Estos resultados junto con los resultados de encuestas para *M. gallisepticum* en poblaciones silvestres, sugieren una interacción huéspedparásito cambiante o evolucionante.

Key words: house finch, *Carpodacus mexicanus, Mycoplasma gallisepticum,* mycoplasmosis, epidemiology, behavioral ecology

Abbreviations: MG = *Mycoplasma gallisepticum*; PCR = polymerase chain reaction; SPA = serum plate agglutination

Since 1994, an epidemic of mycoplasmal conjunctivitis has spread throughout the eastern population of the house finch (*Carpodacus mexicanus*) in the United States (3,4). Prior to 1994, the causative agent of this epidemic, *Mycoplasma gallisepticum* (MG), had not been isolated from this passerine species, suggesting that this is a new host–parasite relationship. In the early years of this epidemic, the infection was associated with high mortality in both wild and captive birds. From 1996 to 1997, the disease was estimated to have reduced the eastern population by at least 20% (12,15). In 1996, the infection spread rapidly through a captive flock in Georgia, causing serious disease and high mortality (9). Similarly, captive house finches housed at the Auburn University aviary in 1996 and 1997 experienced high mortality due to MG conjunctivitis (1).

More recent analysis of the epidemiology of this infection in the wild population suggests that this host–parasite relationship is changing. Recent results from field studies in the southeastern United States document reduced prevalence of conjunctivitis in the wild population (14). In Auburn, AL, the yearly prevalence of disease has remained constant, with approximately 2%–4% of observed birds affected, although the prevalence of clinically ill birds observed during the seasonal peak of conjunctivitis in the late summer and early fall has declined from a high of about 60% in 1996 to 20% in 1998 (14).

To develop a better understanding of the current situation, we analyzed the spread of MG infection through a captive flock established in late summer 1998. The course of clinical disease, serologic response to MG, and infection were monitored in individual birds. In light of the changing epidemiologic patterns observed in the wild, the objective of this study was to determine whether the characteristics of the infection and disease had changed since the earlier study of infection in captive house finches reported by Luttrell *et al.* (9).

MATERIALS AND METHODS

Birds. Hatch-year house finches were captured with wire-mesh basket traps at feeding stations in Lee County, AL, during August 1998. All collecting was conducted under permits from the Alabama Department of Conservation (Montgomery, AL, no. 60) and the Law Enforcement Office of the United States Fish and Wildlife Service (Southeast Regional Office, Atlanta, GA, MB784373-1). All procedures involving live animals were reviewed and approved by the Auburn University IACUC (PRN 0111R2093). The birds were bled at capture by brachial venipuncture. The blood was separated by centrifugation and stored at 4 C until tested. Thirty-eight seronegative hatch-year birds with no evidence of clinical MG infection were quarantined in an outdoor flight cage (4.5 m wide by 4.0 m long by 2.4 m high) at the Auburn University aviary. Feed and water were supplied *ad libitum*. The diet of mixed red and white millet and sunflower seed was supplemented with vitamins and grit. Fresh water, supplemented with sulfadimethoxine (0.125 g/liter) to suppress development of coccidiosis (1), was provided in bowls that were cleaned daily. The birds were quarantined for a minimum of 4 wk before two seropositive birds that had been housed in a different location at the Auburn University aviary were inadvertently introduced into the quarantined flock. These birds were from a large flock of female house finches that had been housed at the aviary since the previous fall and had experienced an outbreak of MG. At the time of introduction, both of these birds were clinically normal. Once conjunctivitis was noted in the flock, all birds were captured, examined, swabbed, and bled. All birds were caught and sampled in this manner every 2 wk from mid-September through the first week of December 1998. The flock was held in captivity through the winter and captured for a final sample in the third week of March 1999.

Lesion scoring. The severity of disease was scored with the following scale: 0 = eye appeared entirely normal; 1 = minor swelling around the eye; 2 = moderate swelling around the eye, with eversion of the conjunctiva and lachrymal secretion present; 3 = severe swelling, with the eye nearly closed by swelling and/or crusting of the secretions.

Serology. The serum was tested for MG-specific antibodies by the serum plate agglutination (SPA) assay (6,8). The degree of agglutination of each sample was scored on a scale of 0–4, and a score of 2 or greater was considered positive.

Detection of MG. The choanal cleft of each bird was swabbed for the detection of MG DNA by polymerase chain reaction (PCR). If the conjunctiva or eyelid was swollen, the conjunctiva was also swabbed. MG DNA was amplified from the material on the swab with MG-specific primers as described previously (7).

Statistical analysis. The average durations of clinical disease and infection were analyzed by the Student paired *t*-test (P-value of ≤ 0.05), and mortality was analyzed by chi-square analysis (P-value of ≤ 0.05).

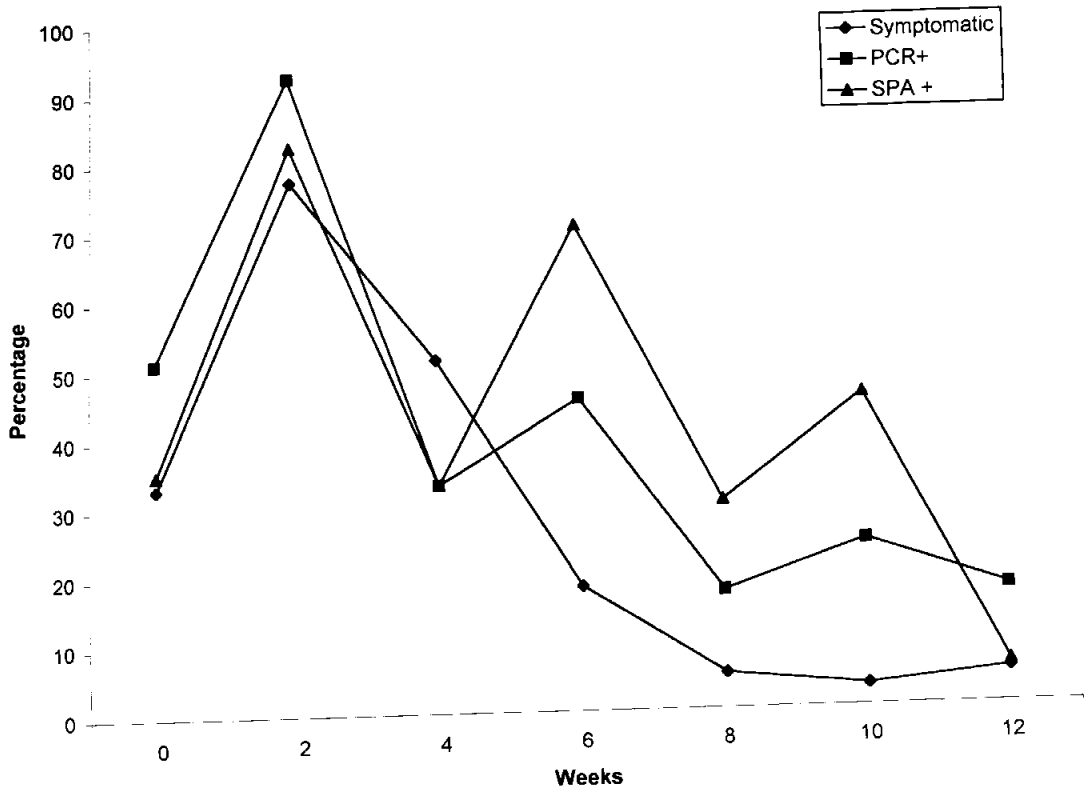

Fig. 1. MG infection in house finches: the percentages of birds that were symptomatic, infected (PCR+), or seropositive (SPA+) during the 12-wk study.

RESULTS

Conjunctivitis was noticed in the flock in mid-September. Thirteen of the 40 birds (33%) in the flock were symptomatic at that time (Fig. 1). MG DNA was amplified by PCR from eight of the affected birds and 10 clinically normal birds. Initially, neither of the two introduced birds was symptomatic nor was MG DNA detected in either of these birds. Two weeks later, 30 birds had conjunctivitis, including one of the introduced birds. Just as rapidly as conjunctivitis spread through the flock, the disease resolved (Fig. 1). Four weeks after the first appearance of disease, only 20 of the birds (50%) had conjunctivitis and 14 birds had recovered clinically. The number of clinically ill birds continued to decline, and within 6 wk of the onset of the disease in this flock, only seven birds (18%) exhibited conjunctivitis. The number of sick birds fluctuated in the later weeks of the study as a few birds experienced recurrent conjunctivitis. The mortality rate during the 12 wk of the study was 8% (3 of 40 birds). The dead birds included two birds from the original quarantined flock as well as one of the introduced birds. Thirty-three (83%) of the 40 birds developed conjunctivitis. Two-thirds of the diseased birds exhibited signs in only one eye, and the disease did not spread from the affected eye to the other eye. The most frequently observed sign was periorbital swelling. Inflammation of the conjunctiva and a watery discharge were also frequently observed. Generally, the signs were not as severe as observed in previous infections in the aviary (Hill, unpubl. obs.). Seventeen birds (52%) received a maximum score of 2 during the course of the disease, nine birds (27%) received a maximum score of 3, and seven birds (21%) received a maximum score of 1.

Table 1. Characteristics of host responses to infection with MG in 1998.

Type of infection	Number of birds	Average no. observations with clinical signs[A]	Average no. observations MG detected[B]	Mortality
Acute	27	1.9 ± 0.8	1.9 ± 0.9	4/27 (15%)
Chronic	10	2.4 ± 0.9	4.4 ± 1.2	7/10 (70%)

[A]The flock was captured every 2 wk, and each bird was assessed for clinical disease and swabbed for PCR detection of MG. The observations at which each bird was ill were summed, and the average for each group was calculated.

[B]The observations at which MG could be detected by PCR were summed, and the average for the group was calculated.

Of the original 38 quarantined seronegative birds, 37 (97%) seroconverted and 32 (84%) developed conjunctivitis. The remaining bird was clinically normal and seronegative throughout the study although MG was detected in this bird on two separate occasions. Only two of the quarantined birds died during the 12 wk of the study.

When the responses of individual birds to infection were compared, two distinct patterns of infection were observed (Table 1). Twenty-seven of the infected birds (66%) experienced an acute, self-limiting infection characterized by seroconversion early in the study and subsequent decline in the SPA scores. Either these birds became seronegative or their SPA scores remained low (2 or less) through the remainder of the study and we could not detect MG in them.

Twenty-three of the 27 birds (85%) that developed an acute infection developed conjunctivitis, while four of these birds never became ill, although they seroconverted and MG was detected by PCR. Of the twenty-three birds that became clinically ill, 19 exhibited conjunctivitis on only one or two observations (Table 1). The ability to detect MG in these birds correlated with conjunctivitis, and MG could be detected for an average of 1.9 observations (Table 1). None of these birds died during the 12 wk that this flock was routinely assessed from September through December 1998, and only four of these birds (15%) died during the winter after the study had been completed (Table 1). The SPA scores peaked during the clinical disease and then declined. Eighteen of the birds (44%) in this group were seronegative within a month of the resolution of conjunctivitis, whereas the remaining nine birds had fluctuating SPA scores of 1 or 2, although MG was not detected at that time in these birds. By all measures employed in this study, this group of birds appeared to have cleared infection.

In contrast, 10 birds (24%) exhibited a distinct response to MG infection characterized by prolonged infection. All 10 of these birds developed conjunctivitis, and two were ill for at least 6 wk and died during the first 8 wk of the study. MG was amplified from these two birds throughout that time, and they remained seropositive. The remaining eight birds initially experienced clinical disease similar to that observed in the 27 birds that experienced an acute infection as described above. The signs observed in these chronically infected birds were no more severe than those observed in the acutely affected group, and the duration of clinical disease was not significantly different between these two groups ($t = -1.47$, $P = 0.08$; Table 1). However, MG could be detected by PCR in these birds for a much longer time ($t = -6.42$, $P = 0.0001$; Table 1), and they remained seropositive throughout the study. Two of these birds also experienced recurrence of mild conjunctivitis. Five of these birds died between the end of this study in December and March when the flock was last examined. In sum, seven of the 10 birds in this group (70%) died between summer 1998 and early spring 1999, compared with only four of the 27 birds (15%) that were infected and recovered ($\chi^2 = 10.64$, $P = 0.001$).

DISCUSSION

Although the epidemic of MG conjunctivitis spread rapidly through the eastern range of the house finch since first appearing in Maryland

in 1994, the prevalence of clinical disease in the wild is declining (12,14). The results from the infection of a captive flock reported here suggest that the change in disease prevalence among wild house finches is the result of a changing host–parasite relationship.

While the results reported here support the changing situation observed in the wild, they also provide an interesting contrast to the earlier observation of a natural MG infection in a captive flock (9). In their study, Luttrell *et al.* (9) reported that the infection spread rapidly and that, once clinical disease appeared, the signs did not resolve. Of the 104 birds included in that study, 43 either died or became sufficiently ill that they were euthanatized. In the current study, we also observed a rapid spread of MG through a captive flock, but the outcome of the infection was quite different. Mortality was much lower than that observed in the 1996 study, and the majority of our birds appeared to have cleared the infection. These two captive studies appear to mirror the changing nature of the epidemic observed in the eastern range of the wild house finch population.

As a consequence of the MG epidemic, the population of house finches in Auburn, like house finch populations across eastern North America, has been under intense natural selection for resistance to the disease. The hatch-year birds used in this study represent the third generation of finches subjected to MG infection. One predicted outcome of such intense selection on multiple generations of finches is increased resistance to mycoplasmosis (2,11). Consistent with this prediction, we observed that the 1998 generation experienced lower mortality and less severe disease after infection with MG compared with the 1996 generation of house finches.

Not only is a host population predicted to evolve in response to infection by a novel pathogen, but the parasite is expected to evolve in response to the environment provided by a new host. One aspect of the parasite that is subject to evolution is virulence. The direction of change in virulence depends on the speed and severity of the pathogenesis caused by the parasite and the parasite's mode of transmission (5,10,13). In some circumstances, reduced virulence is predicted (5,10,13). Thus, the reduced severity of infection observed in our 1998 infection experiment is consistent not only with increased resistance in finches but also with reduced virulence in MG. Moreover, change in host resistance and change in parasite virulence are not mutually exclusive predictions, and we assume that the observed change in disease among exposed house finches is a consequence of evolution of both the host and the parasite. Determining the relative importance of host resistance *vs.* change in parasite virulence in the reduced severity of mycoplasmosis observed in eastern house finches will require experiments with different populations/strains of both the host and the parasite.

REFERENCES

1. Brawner, W. R. I., G. E. Hill, and C. A. Sundermann. Effects of coccidial and mycoplasmal infection on carotenoid-based plumage coloration in male house finches. Auk. 117:952–963. 2000.

2. Darwin, C. On the origin of species by means of natural selection. John Murray, London, England. 1859.

3. Dhondt, A. A., D. L. Tessaglia, and R. L. Slothower. Epidemic mycoplasmal conjunctivitis in house finches from eastern North America. J. Wildl. Dis. 34:265–280. 1998.

4. Fischer, J. R., D. E. Stallknecht, M. P. Luttrell, A. A. Dhondt, and K. A. Converse. Mycoplasmal conjunctivitis in wild songbirds: the spread of a new contagious disease in a mobile host population. Emerg. Infect. Dis. 3:69–72. 1997.

5. Frank, S. A. Models of parasite virulence. Q. Rev. Biol. 71:37–78. 1993.

6. Glisson, J. R., J. F. Dawe, and S. H. Kleven. The effect of oil-emulsion vaccines on the occurrence of nonspecific plate agglutination reactions for Mycoplasma gallisepticum and M. synoviae. Avian Dis. 28:397–405. 1984.

7. Lauerman, L. H. Mycoplasma PCR assays. In: Nucleic acid amplification assays for diagnosis of animal diseases. L. H. Lauerman, ed. American Association of Veterinary Laboratory Diagnosticians, Turlock, CA. pp. 41–43. 1998.

8. Luttrell, M. P., J. R. Fischer, D. E. Stallknecht, and S. H. Kleven. Field investigation of Mycoplasma gallisepticum infections in house finches (Carpodacus mexicanus) from Maryland and Georgia. Avian Dis. 40:335–341. 1996.

9. Luttrell, M. P., D. E. Stallknecht, J. R. Fischer, C. T. Sewell, and S. H. Kleven. Natural Mycoplasma gallisepticum infection in a captive flock of house finches. J. Wildl. Dis. 34:289–296. 1998.

10. May, R. M., and R. M. Anderson. Parasite–host co-evolution. In: Co-evolution. D. J. Futuyma

and M. Slatkin, eds. Sinauer, Sunderland, MA. pp. 186–206. 1983.

11. Nesse, R. M., and G. C. Williams. Why we get sick: the new science of Darwinian medicine. Times Books, New York. 1994.

12. Nolan, P. M., G. E. Hill, and A. M. Stoehr. Sex, size and plumage redness predict house finch survival in an epidemic. Proc. R. Soc. Lond. B 265: 961–965. 1998.

13. Read, A. F. The evolution of virulence. Trends Microbiol. 2:73–76. 1994.

14. Roberts, S. R., P. M. Nolan, L. H. Lauerman, L.-Q. Li, and G. E. Hill. Characterization of the mycoplasmal conjunctivitis epidemic in a house finch population in the southeastern United States. J. Wildl. Dis. 37:80–88. 2001.

15. Sauer, J. R., J. E. Hines, G. Gough, I. Thomas, and B. G. Peterjohn. The North American Breeding Bird Survey results and analysis, version 96.4. Patuxent Wildlife Research Center, Laurel, MD. 1997.

ACKNOWLEDGMENTS

We thank the members of the Hill Laboratory, including Kevin McGraw and Andrew Stoehr, and the Roberts Laboratory, Kaci Klenk, Carrie Roland, and James Welden, for help with the collection of blood and serology and PCR. We also thank Dr. Fred Hoerr, Dr. Sarah Rowe, and Diane Kiser at the C. S. Roberts Veterinary Diagnostic Laboratory in Auburn, AL, Page Luttrell at the Southeastern Cooperative Wildlife Disease Study at the University of Georgia for advice, and Dr. James Wright for his critical review of the manuscript. This work was supported by the National Science Foundation (grant IBN9722171 to G.E.H), an Undergraduate Research Award from the Department of Biological Sciences, Auburn University, the Walter F. Coxe Research Fund of the Birmingham Audubon Society, the College of Science and Mathematics at Auburn University, the Alabama Agricultural Experiment Station, and the Department of Biological Sciences at Auburn University.