

SUSCEPTIBILITY OF WILD SONGBIRDS TO THE HOUSE FINCH STRAIN OF *MYCOPLASMA GALLISEPTICUM*

K. L. Farmer,^{1,2} G. E. Hill,¹ and S. R. Roberts¹

¹ Department of Biological Sciences, Auburn University, Auburn, Alabama 36849, USA

² Corresponding author (email: farmekr@auburn.edu)

ABSTRACT: Conjunctivitis in house finches (*Carpodacus mexicanus*), caused by *Mycoplasma gallisepticum* (MG), was first reported in 1994 and, since this time, has become endemic in house finch populations throughout eastern North America. Although the house finch is most commonly associated with MG-related conjunctivitis, MG has been reported from other wild bird species, and conjunctivitis (not confirmed as MG related) has been reported in over 30 species. To help define the host range of the house finch strain of MG and to better understand the effect of MG on other host species, we monitored a community of wild birds for exposure to MG and conducted experimental infections on nine avian species. For the field portion of our study, we conducted a 9-mo survey (August 2001 to April 2002) of wild avian species in a peri-urban environment on the campus of Auburn University. During this time 358 birds, representing 13 different families, were sampled. No clinical signs of mycoplasmosis were observed in any bird. Thirteen species from nine families had positive agglutination reactions for antibodies to MG, but all birds tested negative by polymerase chain reaction (PCR). Three mourning doves were PCR-positive for MG, but antibodies to MG were not detected. In the experimental infections, we exposed seven native avian species and two cage-bird species to MG (May 2000 to June 2002). After exposure, clinical disease was seen in all four species from the family Fringillidae and in eastern tufted titmice (*Baeolophus bicolor*). In addition, three other species were infected without clinical signs, suggesting that they may represent potential MG reservoirs.

Key Words: *Baeolophus bicolor*, *Carduelis tristis*, *Carpodacus mexicanus*, conjunctivitis, experimental infection, host range, *Mycoplasma gallisepticum*, passerine.

INTRODUCTION

Mycoplasma gallisepticum (MG) was originally isolated from a house finch (*Carpodacus mexicanus*) with conjunctivitis in 1994. Within three years, this disease had spread through the entire eastern population of house finches in North America (Fischer et al., 1997; Dhondt et al., 1998). House finches are the most commonly reported passerine species with MG related conjunctivitis, but conjunctivitis has been reported from over 30 passerine species (Hartup et al., 2000, 2001; Mikaelian et al., 2001). MG infection has not been confirmed in most of these reported conjunctivitis cases, however. In field studies on wild birds, antibodies to MG have been detected by agglutination assays in over 20 wild bird species, including ten species in which conjunctivitis has been reported (Hartup et al., 2000; Luttrell et al., 2001). Although this suggests natural infection, the specificity of these serologic tests in wild bird species other than finches is un-

clear. MG has been confirmed by polymerase chain reaction (PCR) or culture in only six wild avian species: house finch, American goldfinch (*Carduelis tristis*), purple finch (*Carpodacus purpureus*), eastern tufted titmouse (*Baeolophus bicolor*), pine grosbeak (*Pinicola enucleator*), and evening grosbeak (*Coccothraustes vespertinus*) (Fischer et al., 1997; Hartup et al., 2000; Luttrell et al., 2001; Mikaelian et al., 2001). Based on these limited data, the extent of infection within wild bird populations is unknown, and it is unknown whether wild avian species, other than house finches, are potentially affected by the house finch MG epidemic. Based on the list of species from which MG infection has been confirmed, we hypothesize that con-familial species would be more susceptible than more distantly related species.

To estimate prevalence of MG in a local population of songbirds and to help assess the specificity of the agglutination assay, we conducted a 9-mo survey of wild avian

species in a peri-urban environment on the Auburn University campus. To help define the host range of the house finch strain of MG and to better understand the effect of MG on potential target species, we conducted experimental infections on nine avian species.

MATERIALS AND METHODS

Field study

From August 2001 to April 2002, birds were captured in mist nets placed on agricultural research lands immediately adjacent to Auburn University, Lee County, Alabama (32°35'N, 85°28'W) under Federal Banding Permit No. 21661. The area consists of open mowed fields with brushy borders. Each bird was examined for clinical disease and was banded with a US Fish and Wildlife Service identification band. Blood (100 µl) was collected from the brachial vein and a micro tip swab was used to sample the choanal cleft (Roberts et al., 2001; Becton Dickinson and Co., Sparks, Maryland, USA).

Serum samples were tested for antibodies to MG by using a commercial serum plate agglutination (SPA) assay (Luttrell et al., 1996; Intervet Inc., Millsboro, Delaware). In brief, the extent of agglutination was scored after 2 min on a scale from 0 to 4, with a score of ≥ 2 considered positive. We performed PCR using MG-specific primers and DNA extracted from choanal swabs (Roberts et al., 2001). Culture was attempted on 206 birds. For culture, swabs taken from the choanal cleft were placed into 3 ml of SP4 broth preheated to 37 C. After gentle vortexing, the swab was removed and the inoculated SP4 broth (Whitcomb, 1983) was incubated at 37 C for 5 weeks or until a color change indicated growth. Isolates were identified by PCR.

Species selection criteria for experimental infections

In our experimental infections we exposed seven avian species that are native to eastern North America and two cage-bird species to the house finch strain of MG. Four species are in the family Fringillidae: house finch, American goldfinch, pine siskin (*Carduelis pinus*), and purple finch. Natural MG infections have been confirmed in both American goldfinch and purple finch. Conjunctivitis has been reported in pine siskin but MG has not been isolated from this species (Hartup et al., 2000).

The tufted titmouse was selected based on previously reported sero-positive and PCR-positive results from this species (Luttrell et al.,

2001). This is the only wild passerine species outside the family Fringillidae to test positive for MG by PCR (Luttrell et al., 2001). House sparrow (*Passer domesticus*: Passeridae) was included based on previous isolation of MG from this species in India (Jain et al., 1971). Antibodies to MG have been detected in house sparrows in the eastern United States (Stallknecht et al., 1982), and they have been experimentally infected with the R strain of MG, which was isolated from the trachea of infected birds for ten days after exposure. Clinical disease or lesions, however, was not reported (Kleven and Fletcher, 1983). Chipping sparrow (*Spizella passerina*: Emberizidae) was included because conjunctivitis has been observed in this species (Hartup et al., 2001), and sero-positive birds have been reported (Luttrell et al., 2001).

To expand the number of bird families tested without infecting additional wild bird species, we also included two cage-bird species. Zebra finches (*Taeniopygia guttata*) are Australian passerines in the family Estrillidae. As a non-passerine test species we also included budgerigars (*Melopsittacus undulatus*; order Psittaciformes, family Psittacidae). These two bird species are easily maintained in captivity and are readily available; budgerigars are susceptible to infection with the R and P strains of MG (Bozeman et al., 1984; Brown and Butcher, 1991).

Experimental infections with MG

House finches ($n = 5$), American goldfinches ($n = 13$), eastern tufted titmice ($n = 4$), house sparrows ($n = 9$), pine siskins ($n = 9$), chipping sparrows ($n = 10$), and a purple finch ($n = 1$) were captured between May 2000 and July 2002 in Lee County, Alabama, using wire-mesh basket traps and mist nets under a federal collecting permit (MB784373-4) and a permit from the Alabama Department of Conservation (Montgomery, Alabama; No. 12). We also purchased ten budgerigars and nine zebra finches at local pet stores. All procedures involving these birds were approved by the Auburn University Internal Animal Care and Use Committee (0304-R-2271). Each bird was marked with an individually colored leg band. Each species was housed in an individual indoor, temperature-controlled room (1.6 × 2.3 × 2.6 m) with natural light. Except for tufted titmice and the purple finch, all birds were housed as a free flying flock within the room. The purple finch and the tufted titmice were kept in individual wire cages (0.5 m³); the tufted titmice cages were covered in silk foliage to simulate a more wooded surrounding. Birds were fed millet and sunflower seeds and provided water ad libitum.

Diets of chipping sparrows were supplemented with grass seeds; diets of house sparrows and tufted titmice were supplemented with mealworms. After a 1-wk acclimation period, 100 μ l of blood and a choanal swab were collected from each bird. All birds were tested and confirmed to be PCR-negative and sero-negative prior to inoculation. Positive serologic results prior to infection were limited to the four budgerigars, but nonspecific agglutination with the SPA has been reported previously for this species (Bozeman et al., 1984).

After a minimum of 1 mo quarantined, birds were inoculated by placing 10 μ l of SP4 media containing 1×10^7 color changing units (CCU)/ml of MG into each eye. This dose is known to be infective in house finches (Farmer et al., 2002). The MG isolate used on all birds, except the purple finch, was obtained from a house finch from Auburn, Alabama, in 1999 and was two passages from the original isolation. The isolate of MG used to infect the purple finch was obtained from a house finch in Auburn, Alabama, in 2001 and was one passage away from the original culture. After inoculation, birds were monitored daily for the onset of clinical disease. Blood and swabs were collected every 7 to 10 days, for 10 weeks. The severity of conjunctivitis was scored for each eye on a scale of 0 to 3 as described by Roberts et al. (2001) with the addition of a fifth degree (an eye score of 4) in which the bird was completely blind due to conjunctival swelling. At 3 wk postinoculation (PI), MG culture was attempted as previously described. No birds were euthanized during the study, but dead birds collected in good condition were submitted to the Charles S. Roberts Alabama State Veterinary Diagnostic Laboratory (Auburn, Alabama) for necropsy. Submitted birds were examined for gross lesions. Smears of the proventricular mucosa were collected; gram-stained brain sections were collected for West Nile Virus testing by PCR, and sections of intestine were collected for histology and bacteriology.

Serology was performed within 48 hr of collection and samples were tested blind with regard to the birds' clinical disease scores and their previous SPA scores. Averages and standard deviations were performed using Microsoft Excel 2000.

RESULTS

Field study

During the 9-mo field survey, 358 birds, representing 26 species in 13 families, were sampled. These included 53 recaptures. Clinical signs of conjunctivitis were

not observed, and only three birds, all mourning doves, tested positive for MG by PCR. Forty-two birds (13.7%), representing 13 species from nine families, were SPA-positive (Table 1). Antibodies were detected in all three species representing Mimidae and in both species in Paridae. Sero-positive results were detected in three species that were included in the experimental trial (tufted titmouse, chipping sparrow, and house sparrow) (Table 1). All three PCR-positive mourning doves were sero-negative. With regard to the recaptured birds, six (7%) sero-positive birds were captured more than once during the study. Three of the birds, a tufted titmouse, a Northern mockingbird (*Mimus polyglottos*), and a Northern cardinal (*Cardinalis cardinalis*) tested SPA-positive each time they were captured; however, three Northern cardinals changed their serologic status from SPA-negative to SPA-positive or vice versa over a recapture range from 28 to 152 days. MG was not isolated from any of the 206 culture attempts, including the three PCR-positive mourning doves.

Experimental infections with MG

After inoculation, all finches (house finch, American goldfinch, pine siskin, and purple finch) and two of four tufted titmice developed conjunctivitis (Table 2). With the exception of one American goldfinch, all birds that developed signs of conjunctivitis did so within 1 wk PI. The American goldfinch that was normal at 1 wk PI developed conjunctivitis at 10 days PI (Table 3). Only a mild to moderate ocular discharge was observed in seven of nine pine siskins; conjunctivitis was not observed. Variation in the duration and severity of disease, both within and between the species, was observed. Pine siskins exhibited a mild and short-lived clinical disease lasting less than 3 wk (Table 3); this was mirrored by a short-lived antibody response (Fig. 1). The purple finch developed severe conjunctivitis that resolved within 4 wk, although MG (as detected by

TABLE 1. Species and number of wild birds captured in Auburn, Alabama, between August 2001 and April 2002, and tested for *Mycoplasma gallisepticum* by serum plate agglutination. Test results are given as number of positive samples per total number sampled.

Family	Species	Common name	Serology ^a
Columbidae	<i>Streptopelia decaocto</i>	Eurasian collared dove	0/1
Columbidae	<i>Zenaida macroura</i>	Mourning dove	3/54 (2) ^b
Corvidae	<i>Cyanocitta cristata</i>	Blue jay	1/3
Paridae	<i>Poecile carolinensis</i>	Carolina chickadee	2/17 (9)
Paridae	<i>Baeolophus bicolor</i>	Tufted titmouse	4/17 (8)
Troglodytidae	<i>Thryothorus ludovicianus</i>	Carolina wren	0/6 (2)
Troglodytidae	<i>Troglodytes aedon</i>	House wren	0/1
Regulidae	<i>Regulus satrapa</i>	Golden-crowned kinglet	0/5 (1)
Regulidae	<i>Regulus calendula</i>	Ruby-crowned kinglet	0/9 (2)
Turdidae	<i>Catharus guttatus</i>	Hermit thrush	0/3 (1)
Turdidae	<i>Turdus migratorius</i>	American robin	0/2
Mimidae	<i>Dumetella carolinensis</i>	Gray catbird	2/2
Mimidae	<i>Mimus polyglottos</i>	Northern mockingbird	3/11 (5)
Mimidae	<i>Toxostoma rufum</i>	Brown thrasher	4/9 (3)
Parulidae	<i>Dendroica coronata</i>	Myrtle warbler	0/27
Parulidae	<i>Icteria virens</i>	Yellow-breasted chat	0/2
Emberizidae	<i>Pipilo erythrophthalmus</i>	Eastern towhee	0/7 (2)
Emberizidae	<i>Spizella passerina</i>	Chipping sparrow	4/20
Emberizidae	<i>Melospiza melodia</i>	Song sparrow	0/3
Emberizidae	<i>Melospiza georgiana</i>	Swamp sparrow	0/1
Emberizidae	<i>Zonotrichia albicollis</i>	White-throated sparrow	0/27 (4)
Cardinalidae	<i>Cardinalis cardinalis</i>	Northern cardinal	5/49 (14)
Icteridae	<i>Agelaius phoeniceus</i>	Red-wing blackbird	1/1
Icteridae	<i>Molothrus ater</i>	Brown-headed cowbird	1/7
Fringillidae	<i>Carduelis tristis</i>	American goldfinch	6/41
Passeridae	<i>Passer domesticus</i>	House sparrow	6/33

^a Total number of birds with a score of ≥ 2 on rapid agglutination test.

^b Number of birds recaptured.

TABLE 2. Responses of wild birds experimentally inoculated with the house finch strain of *Mycoplasma gallisepticum* (MG) (No. positive individuals per No. tested). Birds were sampled for the presence of MG by polymerase chain reaction (PCR) or serology every 7 to 10 days for 10 weeks between May 2000 and July 2002.

Species	MG PCR				
	Clinical disease	Detection	Serology ^a	MG culture ^b	Mortality
House finch	5/5	5/5	5/5	5/5	0/5
American goldfinch	13/13	13/13	13/13	6/13	2/13
Pine siskin	7/9	9/9	9/9	0/9	3/9
Purple finch	1/1	1/1	1/1	0/1	0/1
Tufted titmouse	2/4	4/4	4/4	1/4	1/4
Chipping sparrow	0/10	0/10	ND ^c	0/10	0/10
House sparrow	0/9	8/9	8/9	0/9	5/9
Zebra finch	0/9	7/9	3/9	0/9	0/9
Budgerigar	0/10	5/10	ND	0/10	0/10

^a Antibodies detected by serum plate agglutination.

^b Birds were cultured at 3 weeks postinoculation.

^c No data were obtained on these species because of ambiguous results.

TABLE 3. The progression of clinical disease (No. positive per No. tested) over 10 weeks in wild birds inoculated with a house finch strain of *Mycoplasma gallisepticum*.

Species	Weeks postinoculation						
	1	2	3	4	6	8	10
House finch	5/5 ^a	5/5	5/5	5/5	4/5	3/5	1/5
American goldfinch	12/13	13/13	11/12	9/12	12/12	7/11	4/11
Pine siskin	7/9	5/9	0/7	0/6	0/6	ND ^b	0/6
Purple finch	1/1	1/1	1/1	1/1	0/1	0/1	0/1
Tufted titmouse	2/4	2/4	2/4	2/4	1/3	0/3	0/3
Chipping sparrow	0/10	0/10	0/10	0/10	0/10	0/10	0/10
House sparrow	0/9	0/9	0/9	0/8	0/8	0/5	0/4
Zebra finch	0/9	0/9	0/9	0/9	0/9	0/9	0/9
Budgerigar	0/10	0/10	0/10	0/10	0/10	0/10	0/10

^a Positive birds scored one or higher in one or both eyes.
^b No data were collected for this species at eight weeks postchallenge.

PCR) and antibodies to MG could still be detected for 10 wk (Fig. 1). Only two tufted titmice developed severe conjunctivitis, but all four developed antibodies that could be detected 8 to 10 wk PI; MG was detectable by PCR in these birds an average of 4 wk after exposure (Fig. 1). The house finches and American goldfinches developed moderate to severe conjunctivitis that took an average of 7 wk to resolve (Fig. 1); four American goldfinches and one house finch remained clinically ill throughout the 10-wk study (Table 3). MG

was detected for an average of 4 wk in the American goldfinches but could be detected in the house finches until clinical disease was resolved. House finches had a longer lasting antibody response than did the American goldfinches (Fig. 1). MG was successfully reisolated from house finches, American goldfinches, and one tufted titmouse (Table 2).

House sparrows, chipping sparrows, zebra finches, and budgerigars did not develop clinical disease. Antibodies to MG, detected in three zebra finches, did not persist beyond the first week. Antibodies were detected from house sparrows for as long as 5 wk PI. Antibodies to MG could not be detected in chipping sparrows or budgerigars because of the ambiguity of the serologic test. MG was detected by PCR in the choanal cleft of house sparrows, zebra finches, and budgerigars, but not in the chipping sparrows (Table 2). MG was detected in three zebra finches, two budgerigars, and two house sparrows for 3 wk after exposure.

For seven of nine species, birds developed a clear antibody response, but the duration of detectable antibodies was variable and most birds tested negative at the conclusion of the study. For both budgerigars and chipping sparrows, individual birds shifted between high agglutination and low agglutination reactions with no

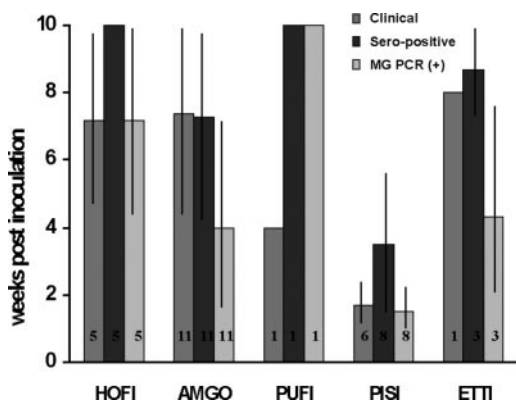


FIGURE 1. Average duration of clinical disease, detectable antibodies, and positive PCR results from species exhibiting clinical disease in response to experimental inoculation with the house finch strain of MG. Bars are SD, numbers are sample size. HOFI = house finch, AMGO = American goldfinch, PISI = pine siskin, PUF1 = purple finch, and ETTI = Eastern tufted titmouse.

consistent pattern or connection to other parameters of disease. Based on these results, SPA results were regarded as inconclusive.

Two American goldfinches and one tufted titmouse died while infected with MG (Table 2). Five house sparrows and three pine siskins died but were not infected with MG. Three pine siskins, four house sparrows, and one tufted titmouse were submitted for necropsy. The Eastern tufted titmouse was positive for West Nile Virus and the lungs had acute multifocal pneumonia. The pine siskins were all positive for megabacteriosis in the proventriculus, and the house sparrows were diagnosed with coccidiosis.

DISCUSSION

This is the first report of mourning doves, or any bird in the order Columbiformes, testing positive for MG by PCR. Although three mourning doves from two capture dates were positive by PCR, the lack of antibodies to MG or culture success suggests that these birds were not currently infected with MG. It is possible that these birds were sampled in the very early stages of infection prior to antibody development, but this possibility is not consistent with negative culture results. Alternately, they may have been infected with a related species of mycoplasma. Although mourning doves were the only PCR-positive species in our field survey, we had 13 SPA-positive species, ten of which had previously been reported with conjunctivitis (Hartup et al., 2001) and seven of which had previously been reported as sero-positive for MG (Hartup et al., 2000; Luttrell et al., 2001). For this same period 21% of house finches caught in the area were sero-positive for MG (unpubl. data).

Experimental infections demonstrate that nonspecific agglutination can occur in wild birds. Ambiguous serologic findings have been reported for poultry (Clisson et al., 1984), house sparrows (Kleven and Fletcher, 1983), and budgerigars (Boze-

man et al., 1984), but little is known about the validity of the test in wild avian species other than house finches. During our experimental infections, the SPA was an accurate and inexpensive tool to monitor antibodies in seven of nine species but was unreliable in budgerigars and chipping sparrows. Chipping sparrows were also one of the 13 SPA-positive wild bird species detected during the field survey and it is possible that false positive results were present in other species. The SPA is a useful tool for screening a large number of birds for antibodies to MG in species for which the validity of the test has been demonstrated or in which infection has been documented. With other species, positive results should be viewed with caution.

All species in the family Fringillidae were susceptible to experimental infection with MG. They developed clinical disease and sero-converted, and MG was detectable by PCR for several weeks PI. Tufted titmice were the only species outside of Fringillidae to develop clinical disease associated with MG infection. House sparrows, zebra finches, and budgerigars were infected without clinical disease. Chipping sparrows were the only species in which infection could not be confirmed by PCR.

One of the most intriguing results in this study is the high susceptibility of American goldfinches to infection with MG. Although house finches and American goldfinches aggregate at feeders and can often be seen feeding side by side, American goldfinches are less frequently observed with conjunctivitis (2%, Hartup et al., 2001; 3%, Luttrell et al., 2001) than are house finches (20%, Dhondt et al., 1998; 27%, Luttrell et al., 2001). The difference in infection rates of house finches and American goldfinches in the wild may be due to many factors, such as lack of transmission of MG between house finches and American goldfinches, inefficient transmission between goldfinches, or variation in susceptibility of the two species. We demonstrated here that American goldfinches

are as susceptible as house finches to experimental infection. Species related differences in the number of reported cases of conjunctivitis are not understood with these species and others and will require further research to identify specific risk factors that may be associated with both MG susceptibility and the potential for transmission.

Both pine siskins and the purple finch were susceptible to infection yet neither species was as severely affected as house finches or American goldfinches. Wild pine siskins have been observed with conjunctivitis (Hartup et al., 2001), although none of the birds tested have been seropositive (Hartup et al., 2000; Luttrell et al., 2001). One previously captured purple finch with conjunctivitis tested positive by PCR and culture; and it, along with two others, tested sero-positive (Hartup et al., 2000). Our study identifies pine siskins as a potential MG carrier. Interpretation of results from the purple finch is difficult based on sample size. The bird did not become as severely infected as the goldfinches and house finches, but this may be because of individual variation and not representative of the purple finch population. Based on results from this single bird, however, purple finches can remain infected for up to 4 wk. We also demonstrate that the SPA test is valid for both of these species.

It has been suggested that tufted titmice may be carriers of MG. Antibodies to MG have been reported from this species (Hartup et al., 2000; Luttrell et al., 2001), but before this study, this was the only species outside of the family Fringillidae from which MG had been detected by PCR but not culture (Luttrell et al., 2001). In the few reports of tufted titmice with conjunctivitis, infection with MG also was not confirmed (Hartup et al., 2001). During our field survey we captured nine tufted titmice, four of which were SPA-positive. One of these four birds was recaptured twice and remained SPA-positive. In our experimental infection of four tufted tit-

mice, they were the only nonfringillid species that developed conjunctivitis in response to infection. This species appears to be less likely to develop clinical disease than house finches or American goldfinches given that only half of the individuals developed conjunctivitis at the same dose that produced disease in 100% of house finches and American goldfinches. A larger number of tufted titmice would be needed to more accurately determine the percentage of individuals that develop clinical disease. However, their highly nervous behavior makes them very difficult to keep in captivity for extended periods.

House sparrows with conjunctivitis have been reported in the wild (Hartup et al., 1998), but our data show that, although MG could be detected by PCR in exposed house sparrows for up to 3 wk PI, they never developed clinical disease. MG has been isolated from both wild and experimentally infected house sparrows (Jain et al., 1971; Kleven and Fletcher, 1983), and in our field survey, six of 33 house sparrows were SPA-positive; none of these birds had clinical disease. If house sparrows function as MG carriers, they are most likely nonclinical carriers.

Budgerigars have been experimentally infected with both the R strain and MG (P) strain isolated from yellow-naped Amazon parrots (*Amazona auropalliata*), and these strains were detected in the trachea 35 and 21 days PI, respectively (Bozeman et al., 1984). In a second study, budgerigars infected with the R strain developed severe clinical signs at 7 days PI; clinical signs were present to 21 days PI (Brown and Butcher, 1991). Clinical signs were not observed in budgerigars infected with the house finch strain of MG in this study, but we were able to detect MG by PCR for 3 wk PI. This suggests that budgerigars are less susceptible to the house finch strain of MG than either the psittacine (P) or poultry (R) strains. As with the budgerigars, zebra finches did not develop clinical signs, but MG was detected in infected birds for up to 3 wk PI. Unfortunately, we

were unable to determine whether chipping sparrows or budgerigars developed antibodies in response to these experimental infections. We were able to detect antibodies in the zebra finches, but only in a few birds and only in the first week PI.

This is the first experimental study in which species other than house finches were challenged with the house finch strain of MG. Although this MG strain infected a wide range of hosts, including a species of psittacine, disease was only confirmed in species in Fringillidae and Paridae. All species representing Fringillidae and the tufted titmice, which represented the only species from Paridae, developed clinical disease. These results are consistent with previous confirmed reports of mycoplasmal conjunctivitis in wild birds, which are currently restricted to house finch, American goldfinch, and evening and pine grosbeak. Blue jays (*Cyanocitta cristata*) (Ley et al., 1996) and tufted titmice can develop conjunctivitis in captivity when exposed to the house finch strain of MG, but naturally acquired disease has not been confirmed in these species. Results from both our field and experimental work indicate that several bird species can be infected with MG without demonstrating clinical disease. This suggests that other species may be involved as reservoirs for this pathogen. Further work to document and understand transmission within such potential reservoirs is critical to our understanding of the emergence and epidemiology of this disease.

ACKNOWLEDGMENTS

We thank the C. S. Roberts Veterinary Diagnostic Laboratory for their help with the necropsies, J. Arial and L. Snowberge for their help with the capture and maintenance of the birds in captivity, and K. Shultze for her work on the field survey. We also thank F. Hoerr, S. Price, and the Hill lab, including L. Siefferman, M. Beck, M. Shawkey, K. Navara, L. Estep, D. Mennill, S. Doucet, H. Mays Jr., and P. Nolan for their critical advice and support with the manuscript. This work was supported by NSF grant DEB-0077804 to G.E.H. and S.R.R., the College of Science and Mathematics at Auburn

University, the Alabama Agricultural Experiment Station, and the Department of Biological Sciences at Auburn University.

LITERATURE CITED

- BOZEMAN, L. H., S. H. KLEVEN, AND R. B. DAVIS. 1984. Mycoplasma challenge studies in budgerigars (*Melopsittacus undulatus*) and chickens. *Avian Diseases* 28: 426–434.
- BROWN, M. A., AND G. D. BUTCHER. 1991. *Mycoplasma gallisepticum* as a model to assess efficacy of inhalant therapy in budgerigars (*Melopsittacus undulatus*). *Avian Diseases* 35: 834–839.
- DHONDT, A. A., D. L. TESSAGLIA, AND R. L. SLOTHOWER. 1998. Epidemic mycoplasmal conjunctivitis in house finches from eastern North America. *Journal of Wildlife Diseases* 34: 265–280.
- FARMER, K. L., G. E. HILL, AND R. S. ROBERTS. 2002. Susceptibility of a naïve population of house finches to *Mycoplasma gallisepticum*. *Journal of Wildlife Diseases* 38: 282–286.
- FISCHER, J. R., D. E. STALKNECHT, M. P. LUTTRELL, A. A. DHONDT, AND K. A. CONVERSE. 1997. Mycoplasmal conjunctivitis in wild songbirds: The spread of a new contagious disease in a mobile host population. *Emerging Infectious Diseases* 3: 69–72.
- GLISSON, J. R., J. F. DAWE, AND S. H. KLEVEN. 1984. The effect of oil-emulsion vaccines on the occurrence of nonspecific plate agglutination reactions for *Mycoplasma gallisepticum* and *M. synoviae*. *Avian Diseases* 28: 397–405.
- HARTUP, B. K., H. O. MOHAMMED, G. V. KOLLIAS, AND A. A. DHONDT. 1998. Risk factors associated with mycoplasmal conjunctivitis in house finches. *Journal of Wildlife Diseases* 34: 281–288.
- , G. V. KOLLIAS, AND D. H. LEY. 2000. Mycoplasmal conjunctivitis in songbirds from New York. *Journal of Wildlife Diseases* 36: 257–264.
- , A. A. DHONDT, K. V. SYDENSTRICKER, W. M. HOCHACHKA, AND G. V. KOLLIAS. 2001. Host range dynamics of mycoplasmal conjunctivitis among birds in North America. *Journal of Wildlife Diseases* 37: 72–81.
- JAIN, N. C., N. K. CHANDIRAMANI, AND I. P. SINGH. 1971. Studies in avian pleuropneumonia-like organisms. 2. Occurrence of mycoplasmas in wild birds. *Indian Journal of Animal Science* 41: 301–305.
- KLEVEN, S. H., AND W. O. FLETCHER. 1983. Laboratory infection of house sparrows (*Passer domesticus*) with *Mycoplasma gallisepticum* and *Mycoplasma synoviae*. *Avian Diseases* 27:308–311.
- LEY, D. H., J. E. BERKHOFF, AND J. M. MCLAREN. 1996. *Mycoplasma gallisepticum* isolated from

- house finches (*Carpodacus mexicanus*) with conjunctivitis. *Avian Diseases* 40: 480–483.
- LUTTRELL, M. P., D. E. STALLKNECHT, S. H. KLEVEN, D. M. KAVANAUGH, J. L. CORN, AND J. R. FISCHER. 2001. *Mycoplasma gallisepticum* in house finches (*Carpodacus mexicanus*) and other wild birds associated with poultry production facilities. *Journal of Wildlife Diseases* 45: 321–329.
- , J. R. FISCHER, D. E. STALLKNECHT, AND S. H. KLEVEN. 1996. Field investigation of *Mycoplasma gallisepticum* infections in house finches (*Carpodacus mexicanus*) from Maryland and Georgia. *Avian Diseases* 40: 335–341.
- MIKAELIAN, I., D. H. LEY, R. CLAVEAU, M. LEMIEUX, AND J-P. BÉRUBÉ. 2001. Mycoplasmosis in evening and pine grosbeaks with conjunctivitis. *Journal of Wildlife Diseases* 37: 826–830.
- ROBERTS, S. R., P. M. NOLAN, AND G. E. HILL. 2001. Characterization of *Mycoplasma gallisepticum* infection in captive house finches (*Carpodacus mexicanus*) in 1998. *Avian Diseases* 45: 70–75.
- STALLKNECHT, D. E., D. C. JOHNSON, W. H. EMORY, AND S. H. KLEVEN. 1982. Wildlife surveillance during a *Mycoplasma gallisepticum* epornitic in domestic turkeys. *Avian Diseases* 26: 883–890.
- WHITCOMB, R. F. 1983. Culture media for spiroplasmas. In *Methods in mycoplasmaology*, Vol. 1, S. Razin and J. G. Tully (eds.). Academic Press, New York, New York, pp. 147–158.

Received for publication 26 March 2004.